

# Hemorrhage

## Hemorrhage

Hemorrhage is the presence of blood outside of a vessel, and may have a number of different causes. Some of the most common causes of hemorrhage in the brain are neoplasia and trauma. Patient presentation and symptoms will vary depending on the location and size of the hemorrhage. Unlike ischemic disease, patient with brain hemorrhage may progress to worse symptoms and outcomes due to swelling or continued bleeding, leading to an increase in intracranial pressure. When hemorrhage is present in the brain, it is defined by it's location and age:

### Location Terms:

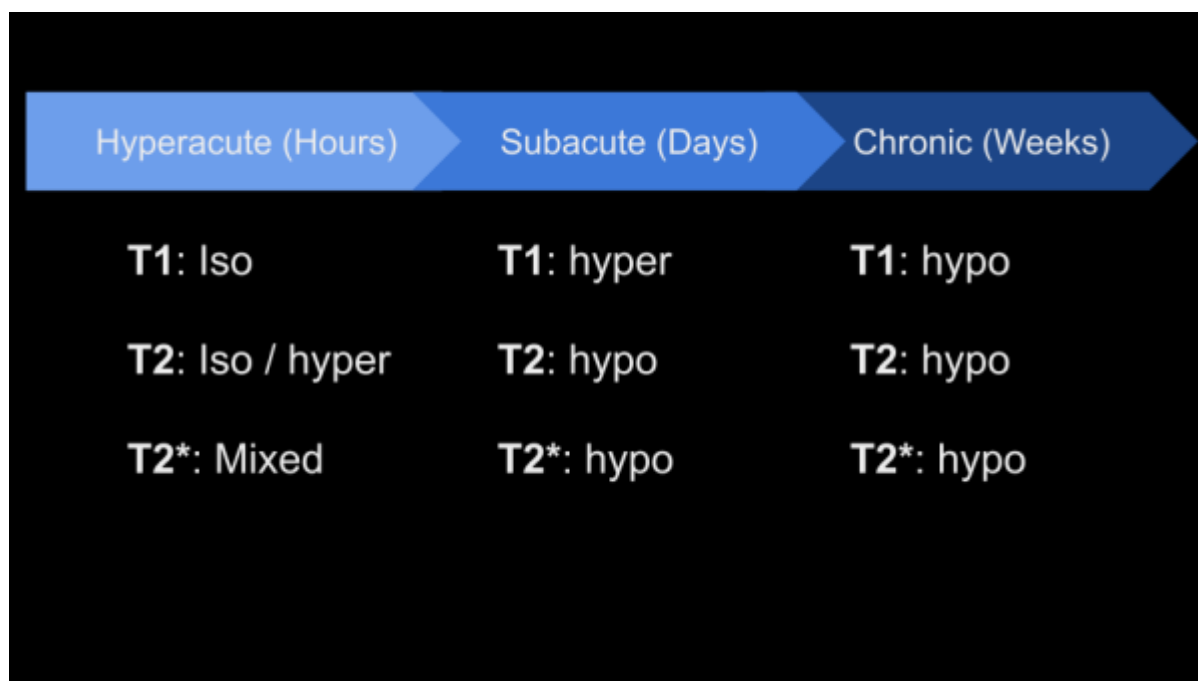
Extra axial (outside the brain)

- Epidural
- Subdural
- Subarachnoid
- Intraventricular

Intra axial (inside the brain tissue)

- May be inside or resulting from a tumor
- May evolve from an ischemic infarct

### Hematoma Progression on T1, T2, and T2\*:



## Important Sequences for Identifying Hemorrhage

### T2\* weighted Imaging

Strong T2\* weighting is especially important for identifying the presence of hemorrhage of any size. The iron content of the blood will lead to dephasing and signal loss, known as 'blooming' artifact or susceptibility artifact. Strong T2\* weighting can only be achieved with a Gradient Echo pulse sequence. Small hemorrhages may be impossible to see on other sequences and weightings. There are many different options and sequences to achieve T2\* weighting, but the most important key parameter is that the TE is long; at least 15-20ms or higher. Below are some different gradient echo options, from most sensitive to least sensitive for detecting hemorrhage:

1. SWAN (GE)/SWI (Siemens) - Susceptibility weighted imaging; very long TE's, 3D Gradient echo
2. MERGE (GE)/MEDIC (Siemens) - Multi echo gradient echo; multiple TE's, 2D or 3D
3. Standard GRE - Make sure it's not a fast or RF spoiled GRE and you can set the TE to about 20ms

### T1 Weighted Imaging

While T2\* weighted images are crucial for detecting hemorrhage, T1 weighted images are valuable as an adjunct in aging hemorrhage. As noted in the chart above, subacute hemorrhage has a characteristic T1 hyperintensity, best assessed with a T1w fast spin echo.

### Case Examples

From:

<https://wiki.virtual-scan.com/> - **Knowledge Portal**

Permanent link:

<https://wiki.virtual-scan.com/doku.php?id=hemorrhage&rev=1777645460>

Last update: **2026/05/01 14:24**

