

# Intervertebral Disc Disease

## Intervertebral Disc Disease (IVDD)

Intervertebral disc disease results from degeneration of the intervertebral disc and is most common in dogs. IVDD can occur in any section of the spine and in any breed of dog, though there are breed and location predilections. IVDD has both external factors like trauma, and genetic factors. The primary genetic predilections are between Chondrodystrophic Breeds and Non-chondrodystrophic Breeds.

Chondrodystrophic breeds have strong genetic predispositions toward degeneration of the nucleus pulposus, which can become calcified and dehydrated at a young age, around 1-3 years old. These breeds are more prone to acute disc herniations and tend to present more acutely.

### Chondrodystrophic Breeds Examples

- Mini dachshund
- Corgi
- French Bulldog
- Cocker Spaniel
- Beagle

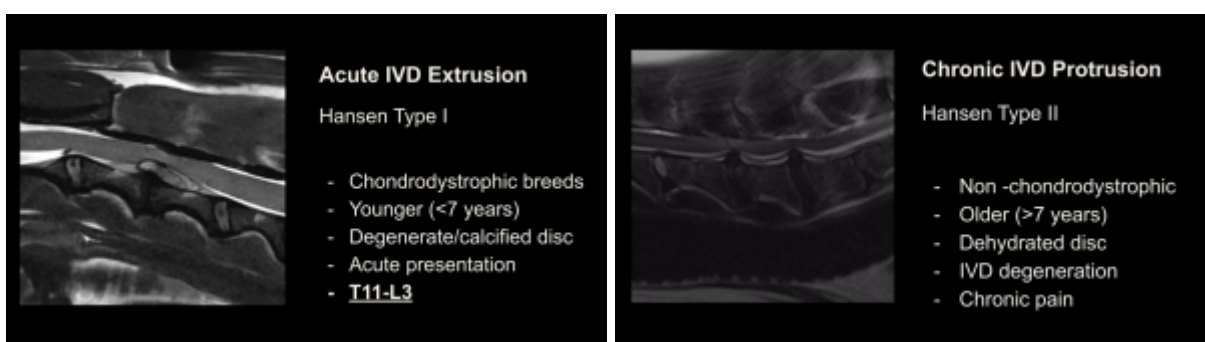
Non-chondrodystrophic breeds tend to undergo a slower degeneration of the disc, and both the nucleus pulposus and the annulus will degrade over time. 7 years or older is more typical for patients to present. These breeds are more prone to disc protrusions and chronic symptoms.

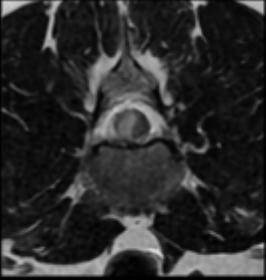
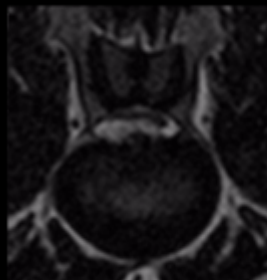
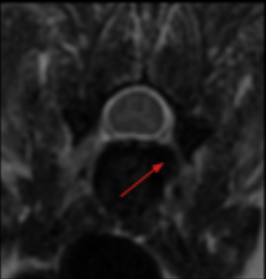
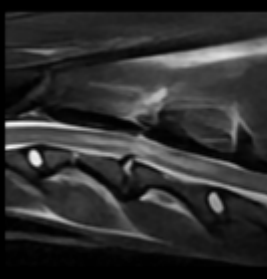

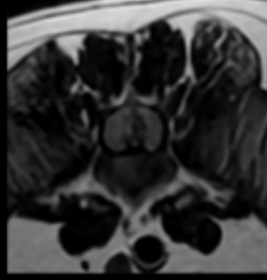
### Non-chondrodystrophic Breeds Examples

- Labrador
- German Shepherd
- Rottweiler
- Doberman

## Types of Disc Herniation

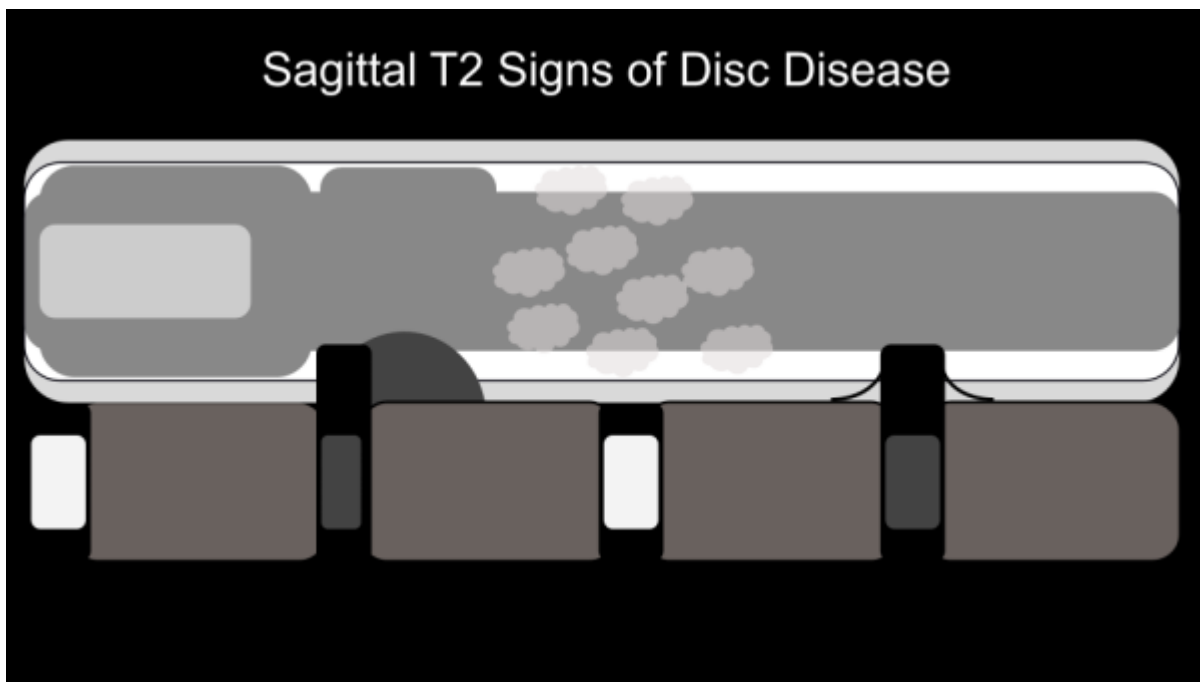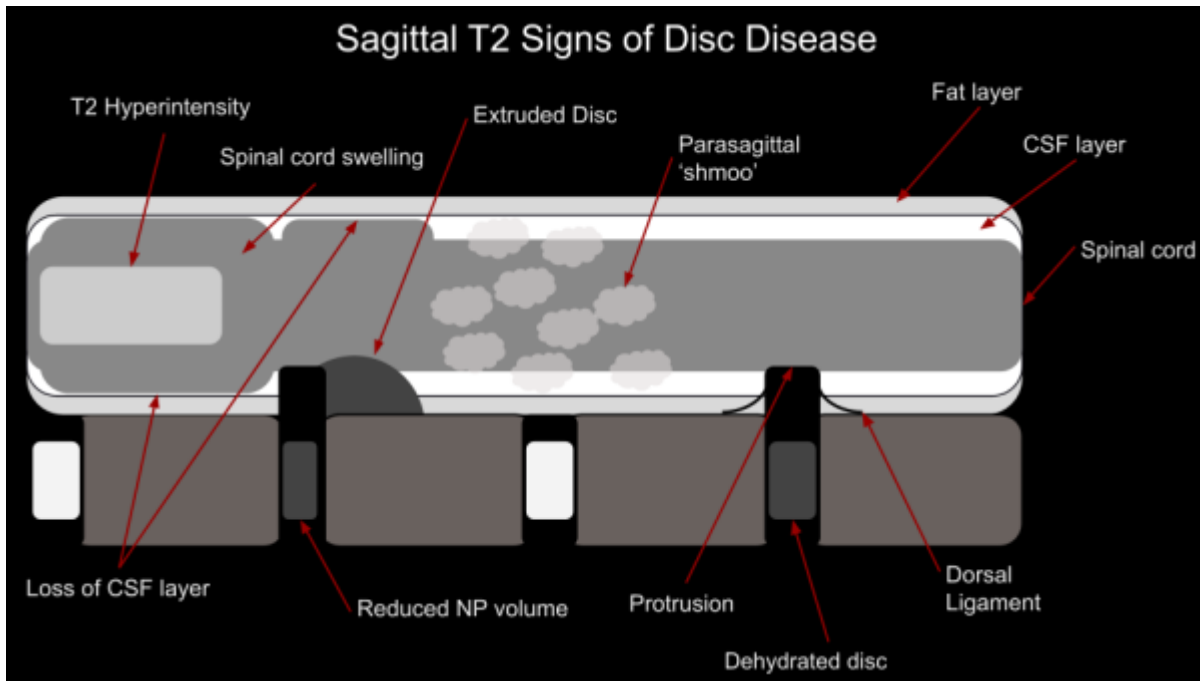
The combination of different external and genetic factors results in different kinds of disc herniations, which will be described here in 8 different categories. Click on each slide to expand

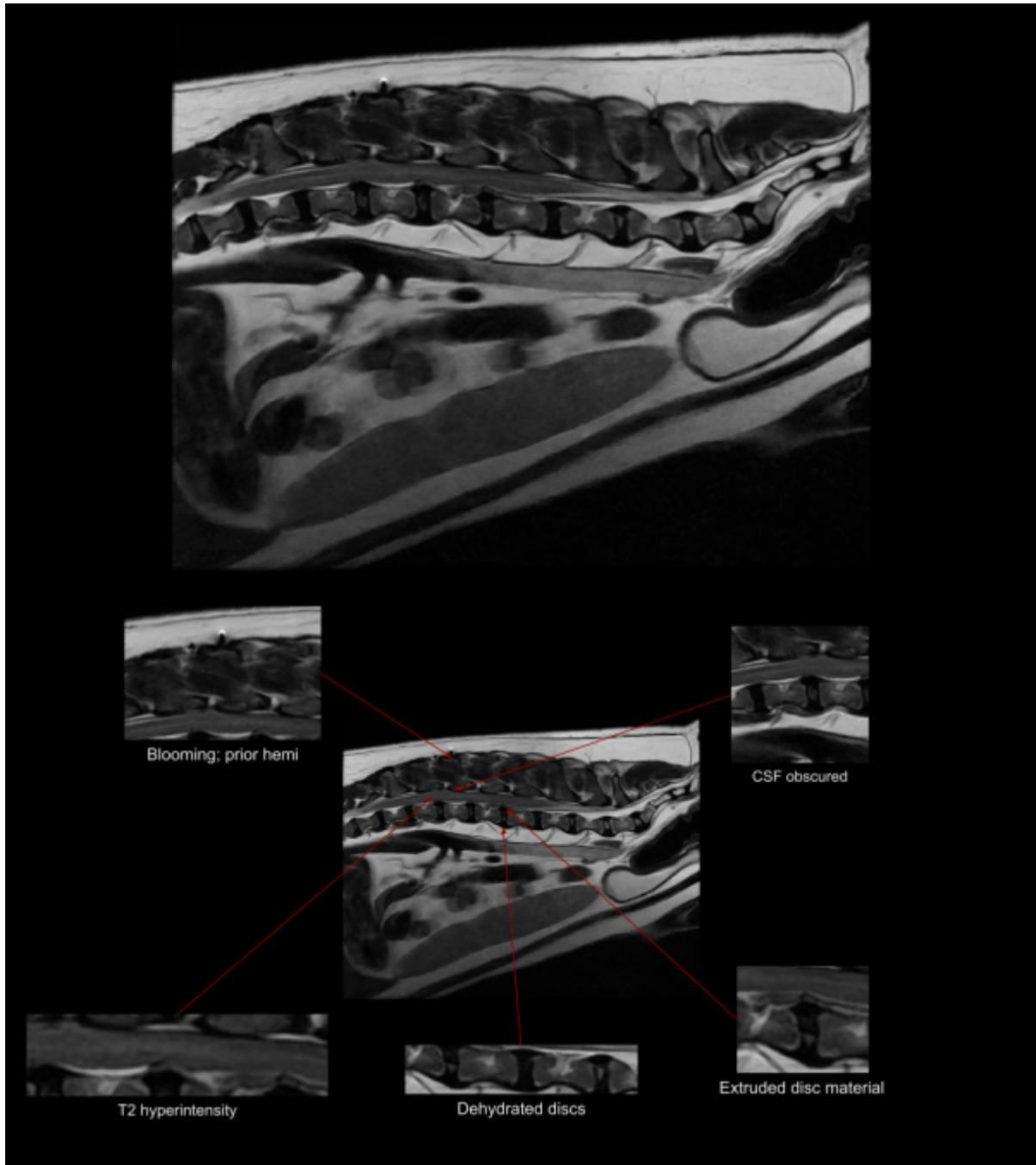


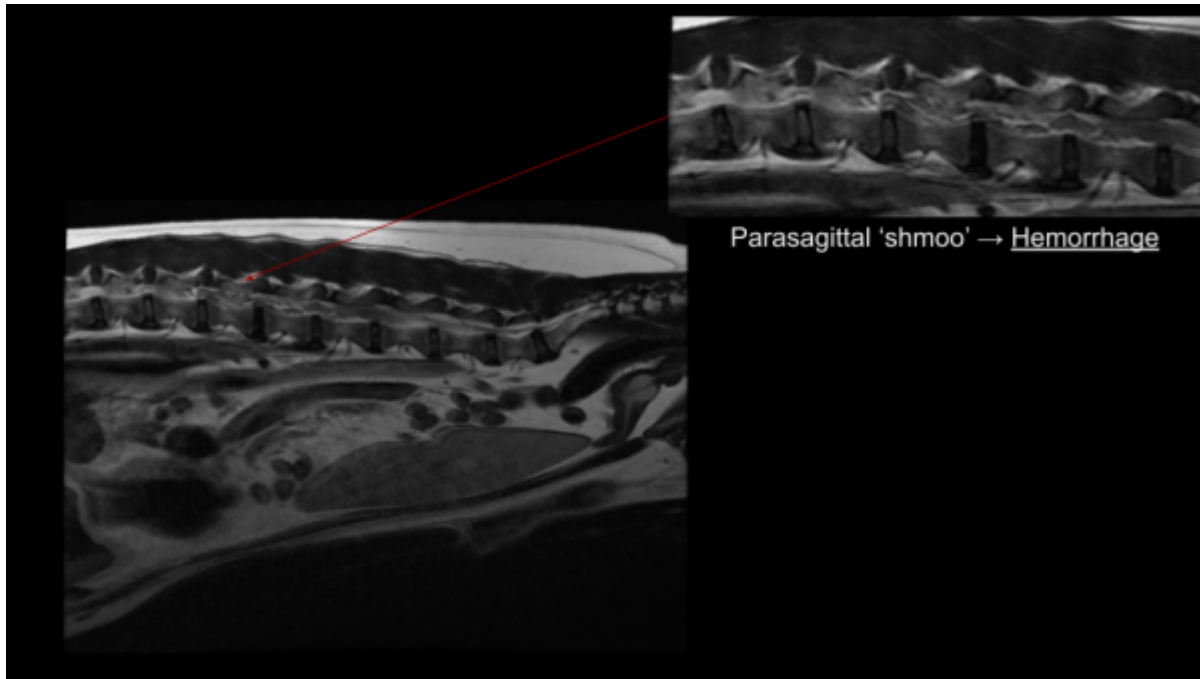
	<p><b>Acute Non-Compressive ANNPE</b></p> <ul style="list-style-type: none"> <li>- High velocity</li> <li>- Low volume</li> <li>- Acute presentation</li> <li>- Non progressive</li> <li>- Reduced volume in IVD</li> <li>- Non degenerate disc</li> <li>- Focal contusion</li> </ul>		<p><b>Hydrated NP Extrusion</b></p> <p>HNPE</p> <ul style="list-style-type: none"> <li>- Non-degenerate disc</li> <li>- Fluid like signal</li> <li>- Partial extrusion</li> <li>- 'Seagull sign'</li> <li>- Acute presentation</li> </ul>
	<p><b>Foraminal Disc Extrusion</b></p> <ul style="list-style-type: none"> <li>- Unilateral signs</li> <li>- Difficult to locate</li> <li>- More common in cervical spine</li> </ul>		<p><b>Traumatic Extrusion</b></p> <ul style="list-style-type: none"> <li>- Acute presentation</li> <li>- Trauma in history</li> <li>- Soft tissue edema</li> <li>- Reduced IVD volume</li> </ul>
	<p><b>IVDE with Hemorrhage</b></p> <p>DEEH</p> <ul style="list-style-type: none"> <li>- Acute extrusion</li> <li>- Extensive hemorrhage</li> <li>- Cranial/caudal</li> <li>- Lateralized</li> <li>- Acute presentation</li> </ul>		<p><b>Intradural/Intramedullary IIVDE</b></p> <ul style="list-style-type: none"> <li>- Disc material within spinal cord</li> <li>- Edema</li> <li>- Uncommon</li> <li>- Linear tract</li> </ul>

### How to Find the Disc

Because it is too time consuming to scan 20 or more discs in the axial plane to find the one disc causing symptoms, the most important first step to scan a high quality sagittal T2, and looks for signs of disc extrusion, and then acquire focused axial slices. Below are slides displaying the various signs of disc extrusion that may be seen on that first sagittal T2.







From:  
<https://wiki.virtual-scan.com/> - Knowledge Portal

Permanent link:  
<https://wiki.virtual-scan.com/doku.php?id=ivdd&rev=1780692995>

Last update: 2026/06/05 20:56

