

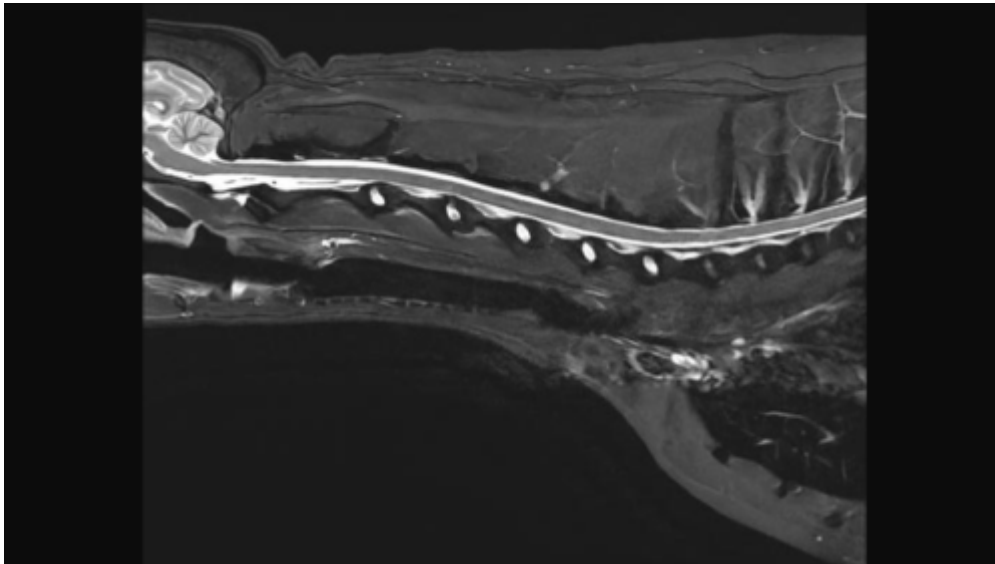
Cervical Spine MRI

Scan Coverage and Planning

Cervical Spine Anatomy page in development.

Sagittal Plane

On the axial and dorsal scout imaging, plan the slices parallel to the center of the spinal cord. On the sagittal scout image, center the FOV on C5. For each patient, the FOV should be re-sized to include the Cerebellum to include the T3 vertebral body. On the dorsal scout image, add enough slices to cover the entire vertebral body out to the transverse processes. **Be sure to use an ODD number of slices. This will ensure that the center slice is in true midline.**



Axial Plane

There are two common variations for planning axial slices in the cervical spine, parallel to the intervertebral disc or perpendicular to the spinal cord. Both variations will yield diagnostic images, so be sure to **check clinician preference**. In the image below, axial slices prescribed parallel to the disc are in orange, and slices prescribed perpendicular to the cord are in yellow. Center the FOV in the middle of the intervertebral disc and check dorsal images to ensure that the slices are not tilted to the left or right. If patient positioning is suboptimal, it may be necessary to rotate the slices to match any side-to-side curve of the neck. If axial slices are being prescribed caudally toward C5/C6/C7, check axial and dorsal images to ensure wrap won't occur.



Dorsal Plane

The dorsal plane angulation is tailored to the clinical scenario, and may not be consistent between

exams. A sample slice planning is below in [orange](#). Due to the natural curve of the spine, there isn't one angle that will get all the spinal cord in one slice, to be sure to adjust the angle to best emphasize pathology noted on prior axial or sagittal images. It is good practice to extend slice coverage ventrally beyond the vertebral bodies, as the [Brachial Plexus](#) nerves exit ventrocaudally from C4/5 to T1/2. Incidental findings are also frequently located on the dorsal plane (Right image, red arrow)



Typical Scan Protocol

Sagittal T2
Sagittal STIR
Sagittal T1
Axial T2
Axial T1
Contrast
Sagittal T1
Axial T1

Recipes for Cervical Spine Sequences

Sagittal T2

In Plane Resolution	.6mm x .6mm
TR	3000+
TE	85-120
ETL	16-24

From:
<https://wiki.virtual-scan.com/> - **Veterinary MRI Wiki**

Permanent link:
https://wiki.virtual-scan.com/doku.php?id=library:cervical_spine&rev=1740456890

Last update: **2025/02/25 04:14**

