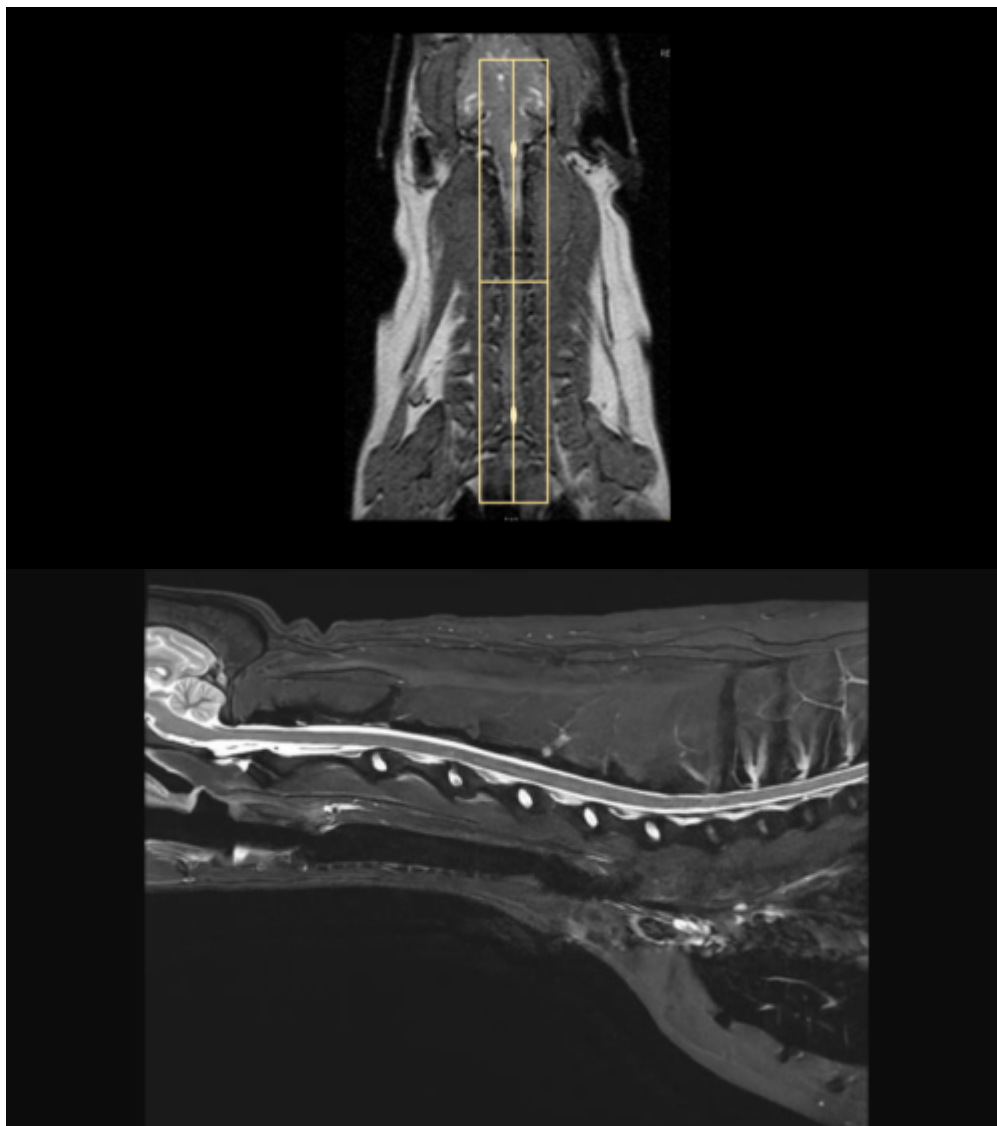


Cervical Spine MRI

Scan Coverage and Planning

Sagittal Plane

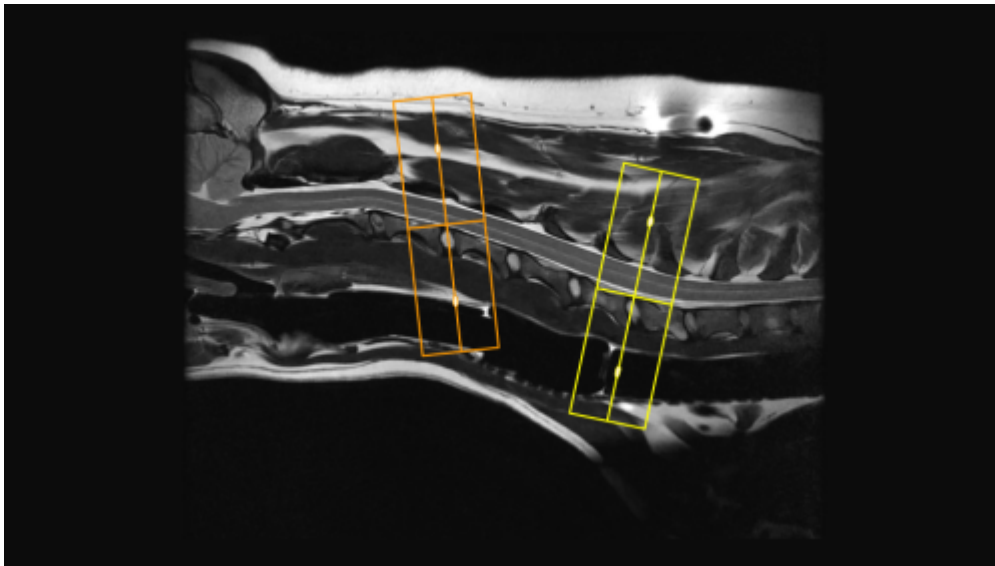
On the axial and dorsal scout imaging, plan the slices parallel to the center of the spinal cord. On the sagittal scout image, center the FOV on C4/5. For each patient, the FOV should be re-sized to include the Cerebellum to include the T3 vertebral body. On the dorsal scout image, add enough slices to cover the entire vertebral body out to the transverse processes. **Be sure to use an ODD number of slices. This will ensure that the center slice is in true midline.**



Axial Plane

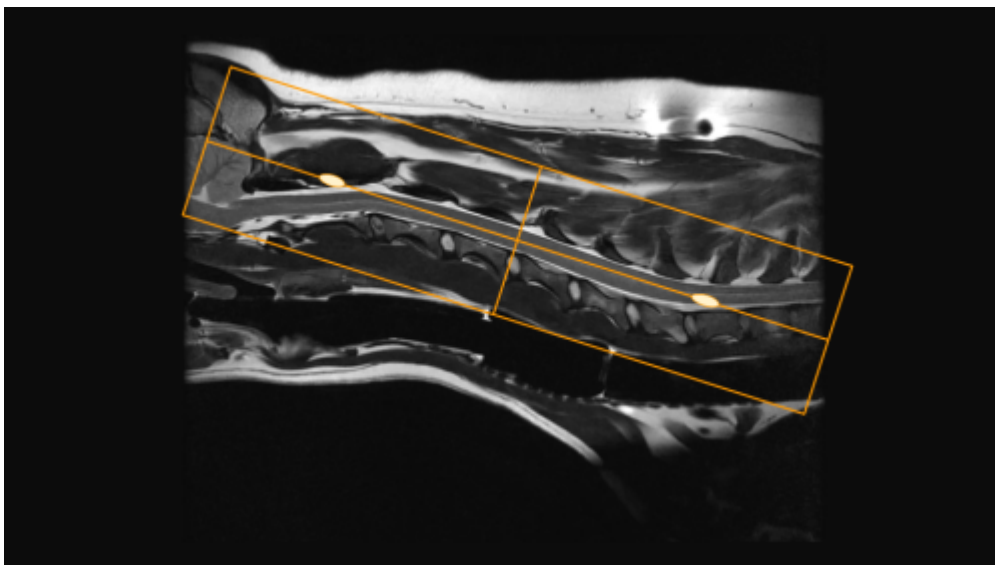
There are two common variations for planning axial slices in the cervical spine, parallel to the intervertebral disc or perpendicular to the spinal cord. Both variations will yield diagnostic images, so be sure to **check clinician preference**. In the image below, axial slices prescribed parallel to the

disc are in orange, and slices prescribed perpendicular to the cord are in yellow. Center the FOV in the middle of the intervertebral disc and check dorsal images to ensure that the slices are not tilted to the left or right. If patient positioning is suboptimal, it may be necessary to rotate the slices to match any side-to-side curve of the neck. If axial slices are being prescribed caudally toward C5/C6/C7, check axial and dorsal images to ensure wrap won't occur.



Dorsal Plane

The dorsal plane angulation is tailored to the clinical scenario, and may not be consistent between exams. A sample slice planning is below in orange. Due to the natural curve of the spine, there isn't one angle that will get all the spinal cord in one slice, so be sure to adjust the angle to best emphasize pathology noted on prior axial or sagittal images. It is good practice to extend slice coverage ventrally beyond the vertebral bodies, as the Brachial Plexus nerves exit ventrocaudally from C4/5 to T1/2. Incidental findings are also frequently located on the dorsal plane (Right image, red arrow)





Typical Scan Protocol

The protocol below represents a full cervical spine exam. There is variation depending on the clinical question and clinician preference. The **minimum** recommended sequences are in bold text. **It is highly recommended to include at least 1 sequence, either T2 or STIR, in the dorsal plane and at least 1 sequence with fat saturation post contrast** For more technical details, see the Protocol Page [here](#).

Sagittal T2

Sagittal or Dorsal STIR

Sagittal T1

Axial T2

Axial T1

Contrast

Sagittal T1 C+

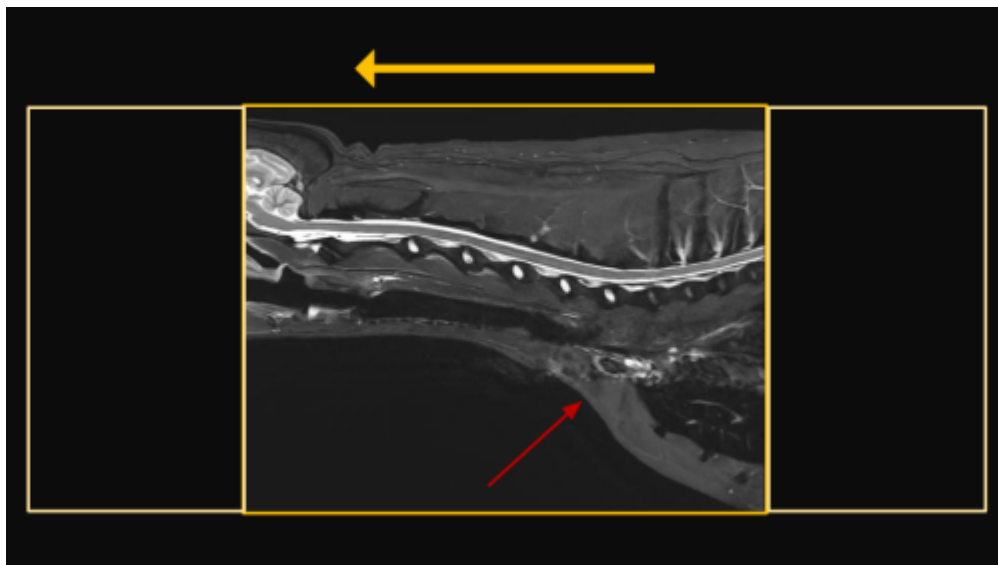
Axial T1 C+

Tips and Tricks

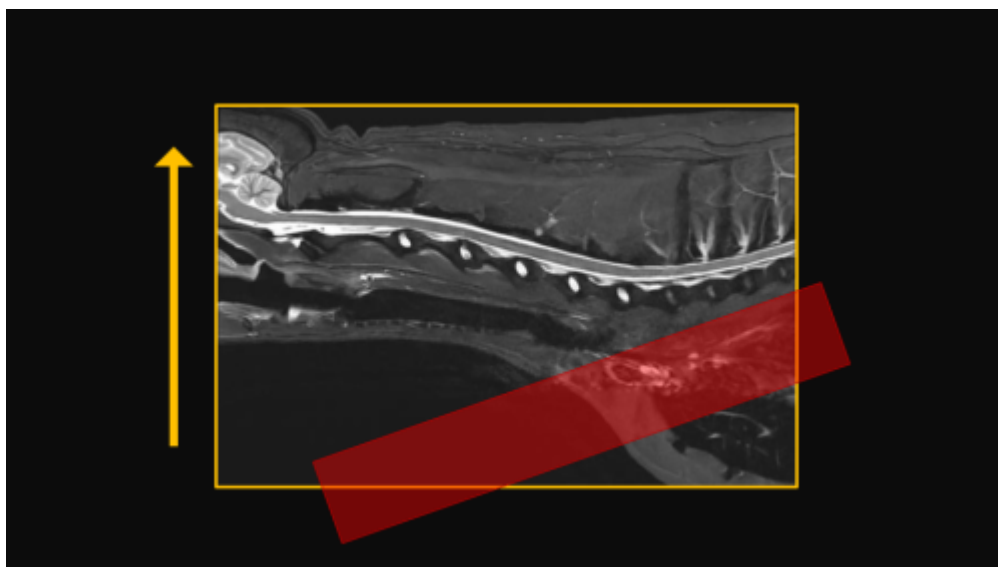
Selecting Phase Direction

In the cervical spine, either A/P or S/I may be selected, but require slightly different acquisition strategies. If choosing the phase direction S/I, motion artifact from respiration and flow the vessels in the cranial thorax will propagate S/I. Unlike awake human patients, there should be no motion artifact from swallowing. In the S/I direction there will be anatomy that extends beyond the FOV, and will require significant oversampling to prevent wrap artifact. This can add quite a bit of time, but will afford some extra SNR, so it may be possible to reduce time by reducing NEX/Averages. Note the flow artifact from the vessels (red arrow). If selecting the phase direction as A/P, it is possible to not only remove all the oversampling, but even to reduce the phase FOV to further reduce time. It is necessary with this method to prescribe a sat band over the cranial thorax to prevent flow artifact from propagating through the caudal cervical spine. It is important to note, this is not an appropriate method when brachial plexus pathology is suspected, as the sat band will obscure the nerve bundles.

Phase S/I



Phase A/P



From:
<https://wiki.virtual-scan.com/> - Knowledge Portal

Permanent link:
https://wiki.virtual-scan.com/doku.php?id=library:cervical_spine&rev=1746755483

Last update: 2025/05/09 01:51

