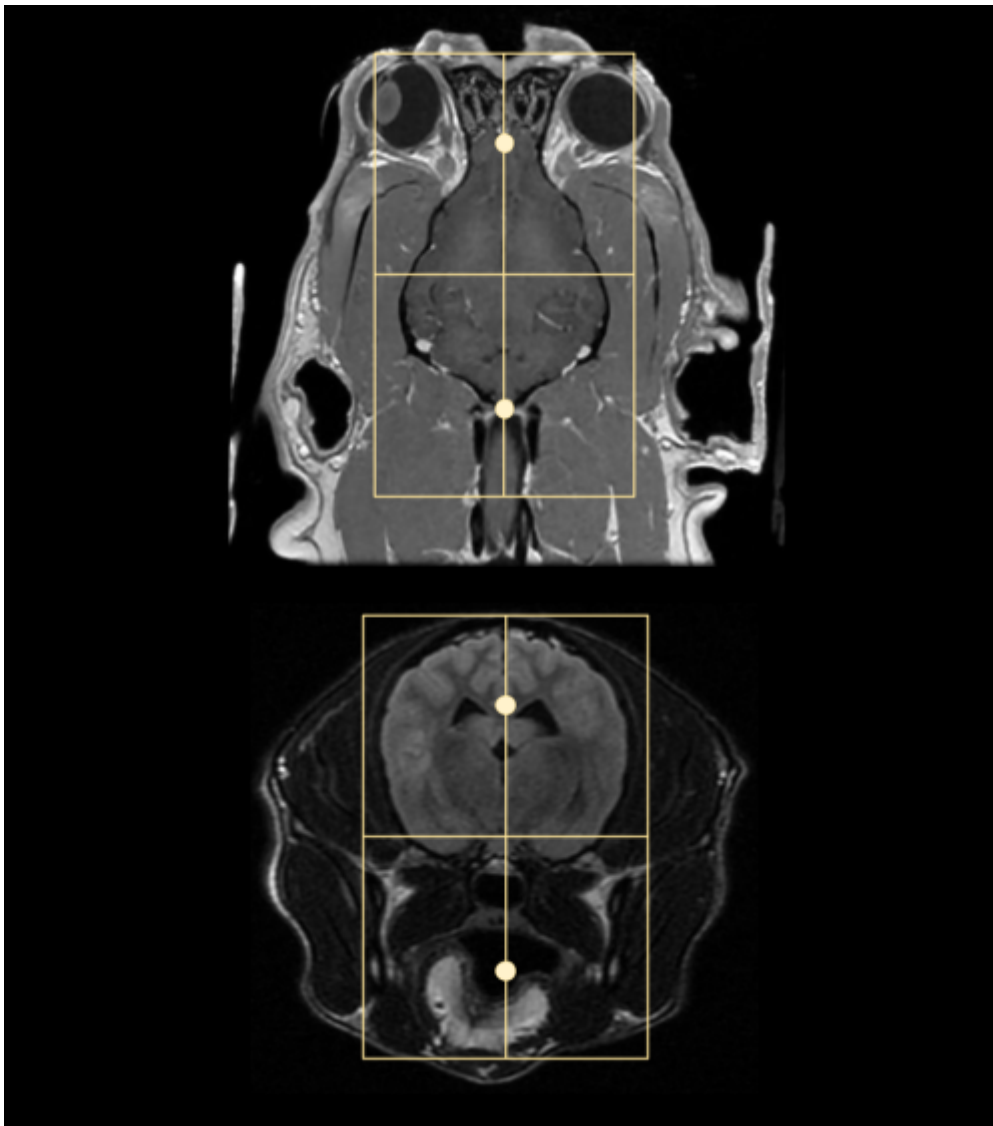


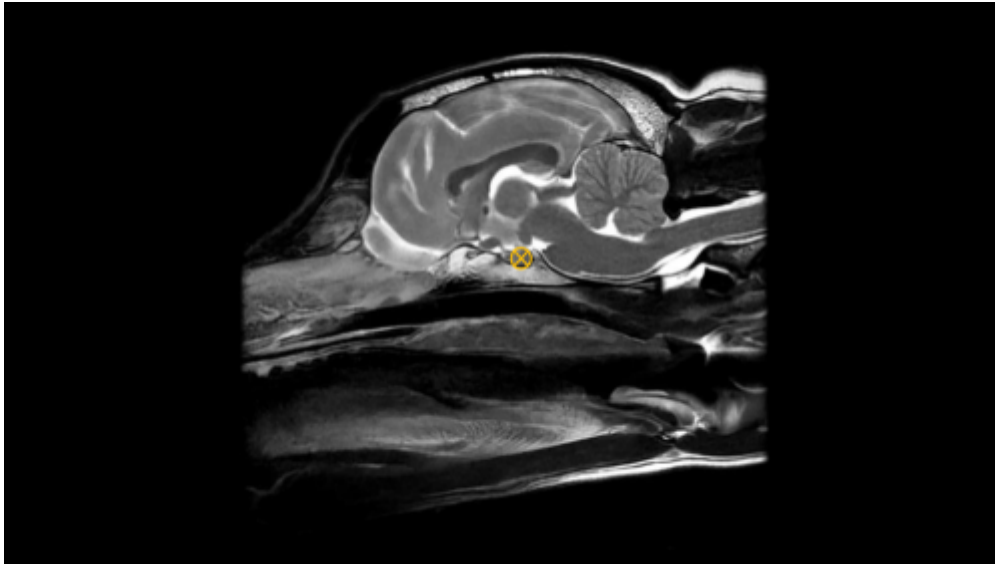
Brain

Scan Coverage and Planning

Sagittal Plane

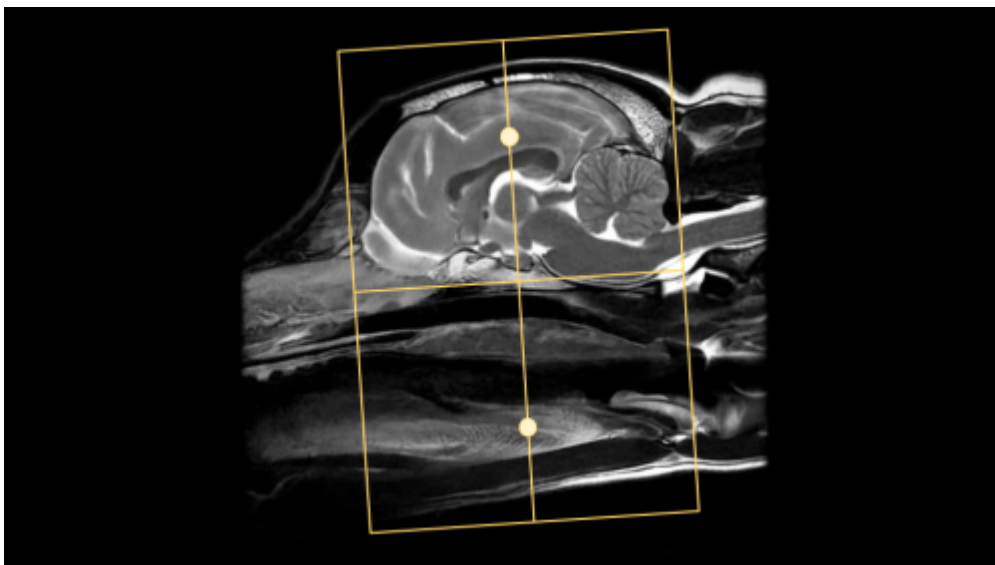
On the 3 dorsal and axial scout images, plane the slices parallel to the midline of the brain, along the sagittal sinus. On the sagittal scout image, center the FOV on the pituitary gland (noted by the X). resize the FOV to include the orbit to C1/2. Add enough slices to include both orbits. **Be sure to use an odd number of slices to ensure the center slice is at true midline.** If the slice is at true midline, the interthalamic adhesion will be seen as a circle surrounded by CSF.

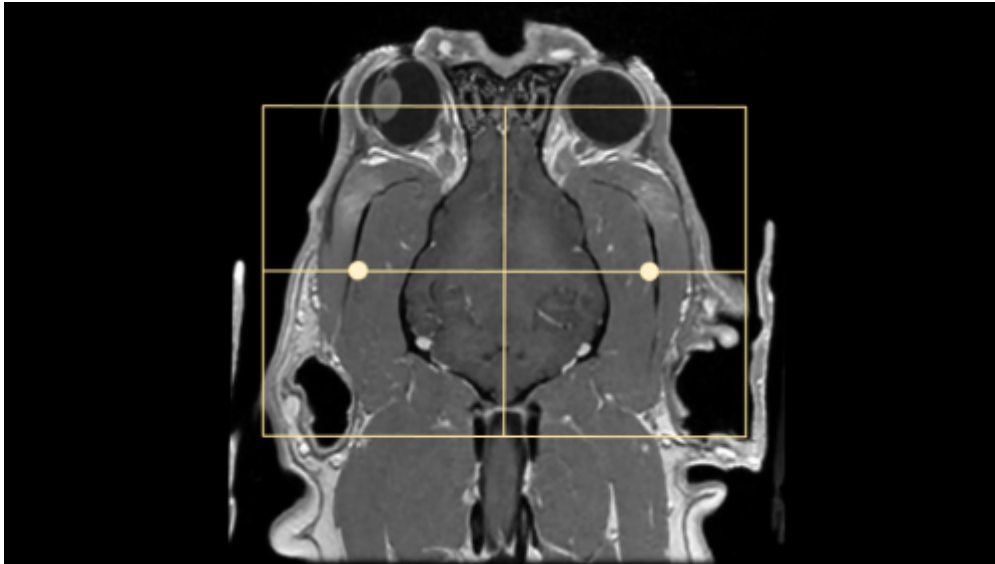




Axial Plane

On a true mid sagittal image, place 1 slice in the middle of the interthalamic adhesion, and add enough slices to cover from in front of the olfactory bulb to past the foramen magnum. Angle the slices perpendicular to the hard palate. Check the dorsal and axial images for rotation, and ensure the slices are also perpendicular with the longitudinal fissure of the brain. The FOV is up to clinician preference, but it is good practice to include the entire head, as pathology may be seen in the musculature and in the ears as well as in the brain.





Dorsal Plane

From:

<https://wiki.virtual-scan.com/> - Knowledge Portal

Permanent link:

https://wiki.virtual-scan.com/doku.php?id=library:mri_brain&rev=1740517996

Last update: 2025/02/25 21:13

