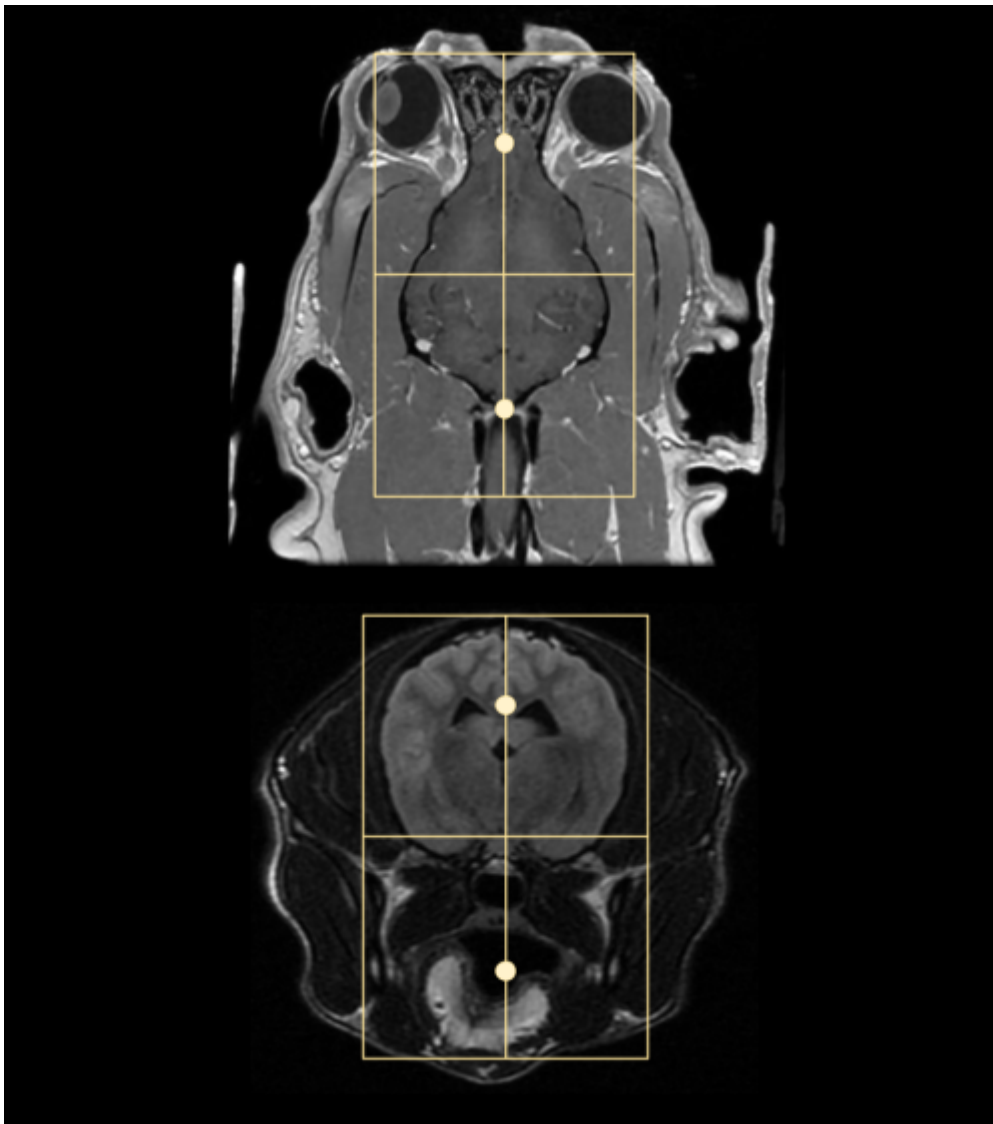


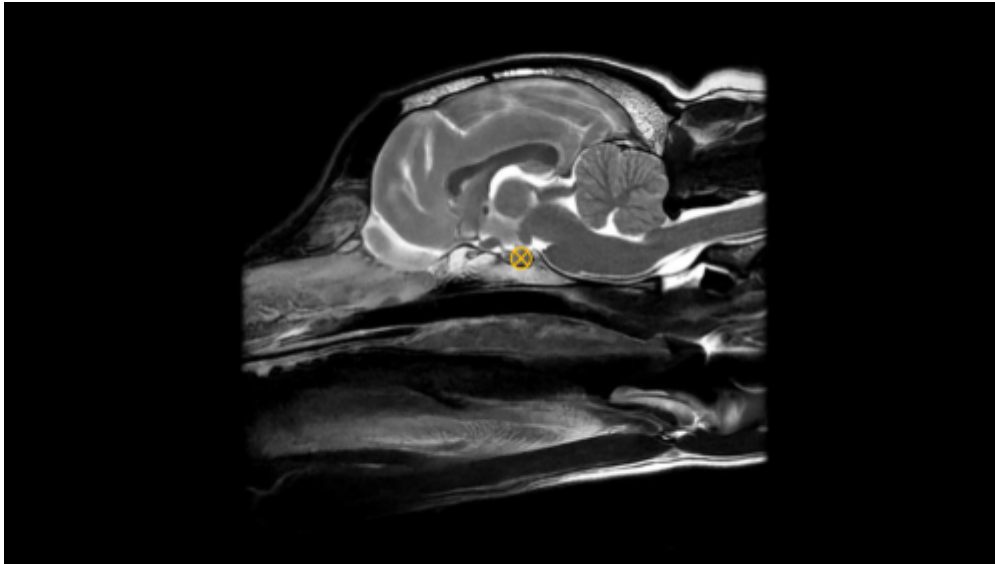
Brain

Scan Coverage and Planning

Sagittal Plane

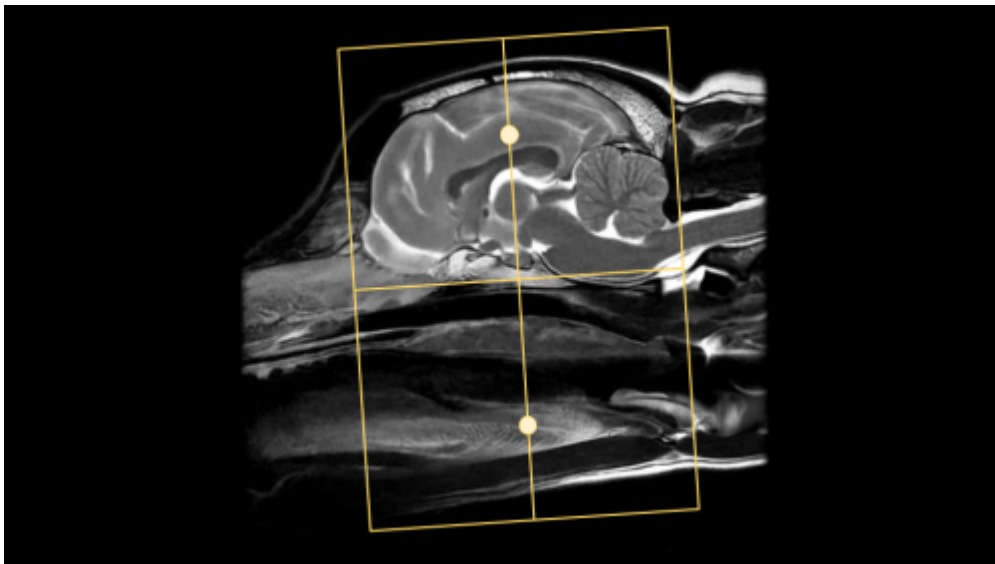
On the 3 dorsal and axial scout images, plane the slices parallel to the midline of the brain, along the sagittal sinus. On the sagittal scout image, center the FOV on the pituitary gland (noted by the X). resize the FOV to include the orbit to C1/2. Add enough slices to include both orbits. **Be sure to use an odd number of slices to ensure the center slice is at true midline.** If the slice is at true midline, the interthalamic adhesion will be seen as a circle surrounded by CSF.





Axial Plane

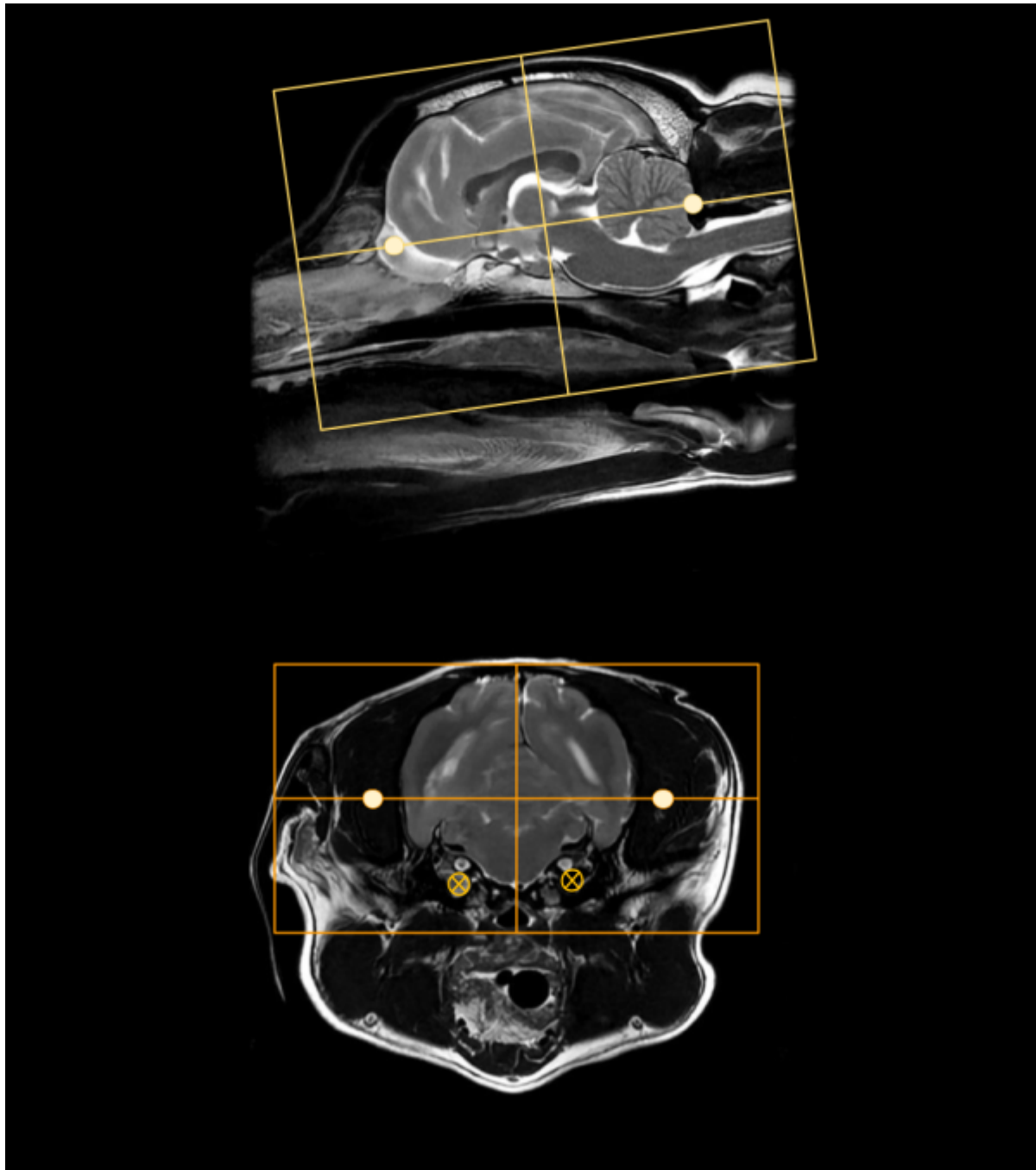
On a true mid sagittal image, place 1 slice in the middle of the interthalamic adhesion, and add enough slices to cover from in front of the olfactory bulb to past the foramen magnum. Angle the slices perpendicular to the hard palate. Check the dorsal and axial images for rotation, and ensure the slices are also perpendicular with the longitudinal fissure of the brain. The FOV is up to clinician preference, but it is good practice to include the entire head, as pathology may be seen in the musculature and in the ears as well as in the brain. Note the muscle atrophy seen on the R side of the post contrast axial image to the right as an example.





Dorsal Plane

On a mid sagittal image, plan slices parallel to the brainstem/cranial spinal cord. There is some anatomic and positional variation with these landmarks, so if neither seems like an appropriate angle, it is also acceptable to plan dorsal slices parallel with the hard palate. The coverage should include at a minimum the bullae to the top of the head. The bullae can be easily located on an axial image, approximately where the facial and vestibulocochlear nerves are visualized. these are marked with small X's on the axial image to the right.



Typical Scan Protocol

The protocol below represents a full brain exam. There is variation depending on the clinical question and clinician preference. The **minimum** recommended sequences are in bold text. Note that some sequences such as the DWI have specific use cases and should be considered required if their indication is present, ie if an ischemic stroke is the clinical question, don't skip the DWI.

Sagittal T2

Axial T2

Axial T2*

Axial T2 FLAIR

Axial DWI

Axial T1

Contrast

Sagittal T1

Axial T1

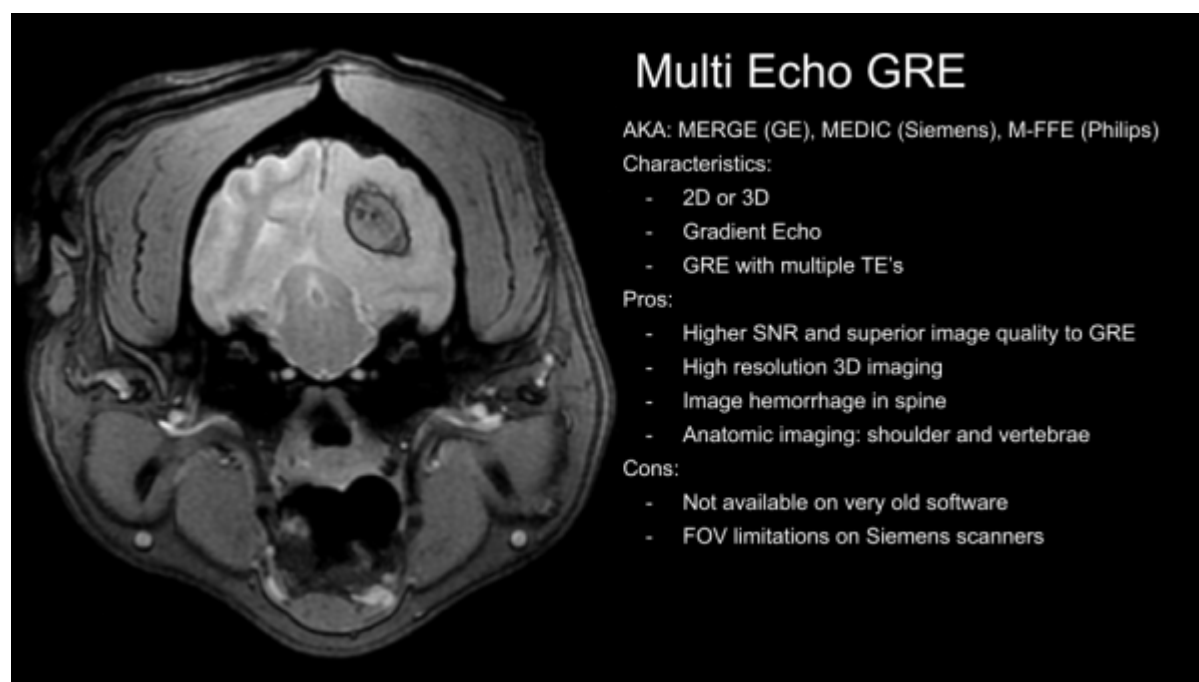
Dorsal T1

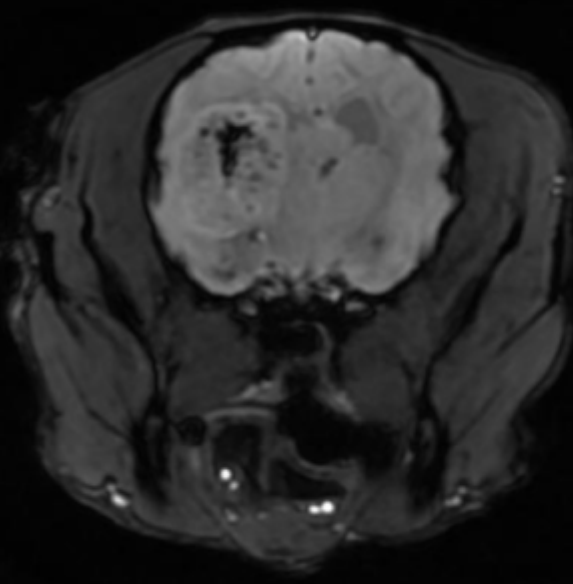
Tips and Tricks

Sequence Substitutions

With Brain MRI in particular, there are quite a few sequence variations that may be encountered or substituted. These different may provide the same or similar image contrast, but have different SNR, be 3D vs 2D, or have additional special properties. As with all things in MRI, there are trade-offs and pros/cons with each sequence choice that will be noted below. The different sequences will be categorized by their image contrast. Please note that some sequences will be vendor or software level specific, so may not be available on every scanner.

T2* Contrast





3D Susceptibility Weighted Imaging

AKA: SWAN (GE), SWI (Siemens), SWIp (Philips)

Characteristics:

- 3D
- Flow Compensated Gradient Echo
- Longer TEs; 25-40ms

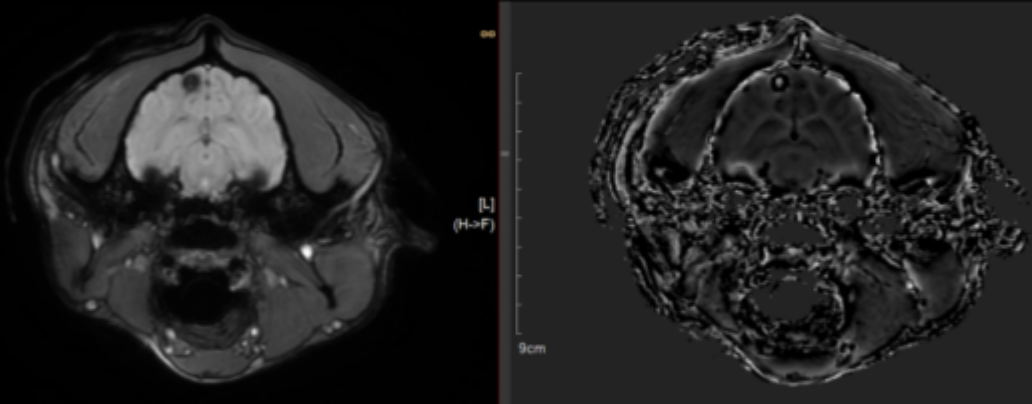
Pros:

- SWI>MEDIC>GRE, most sensitive for hemorrhage
- Newer software: Phase sensitive Image differentiates calcium and hemorrhage
- Black Blood Angiography

Cons:

- Not great for spine imaging
- Phase wrap from large collections of hemosiderin
- Newer software only

Phase Wrap on SWI Phase Image (White in black)



T1 Contrast

From:

<https://wiki.virtual-scan.com/> - Knowledge Portal

Permanent link:

https://wiki.virtual-scan.com/doku.php?id=library:mri_brain&rev=1741141090

Last update: **2025/03/05 02:18**

