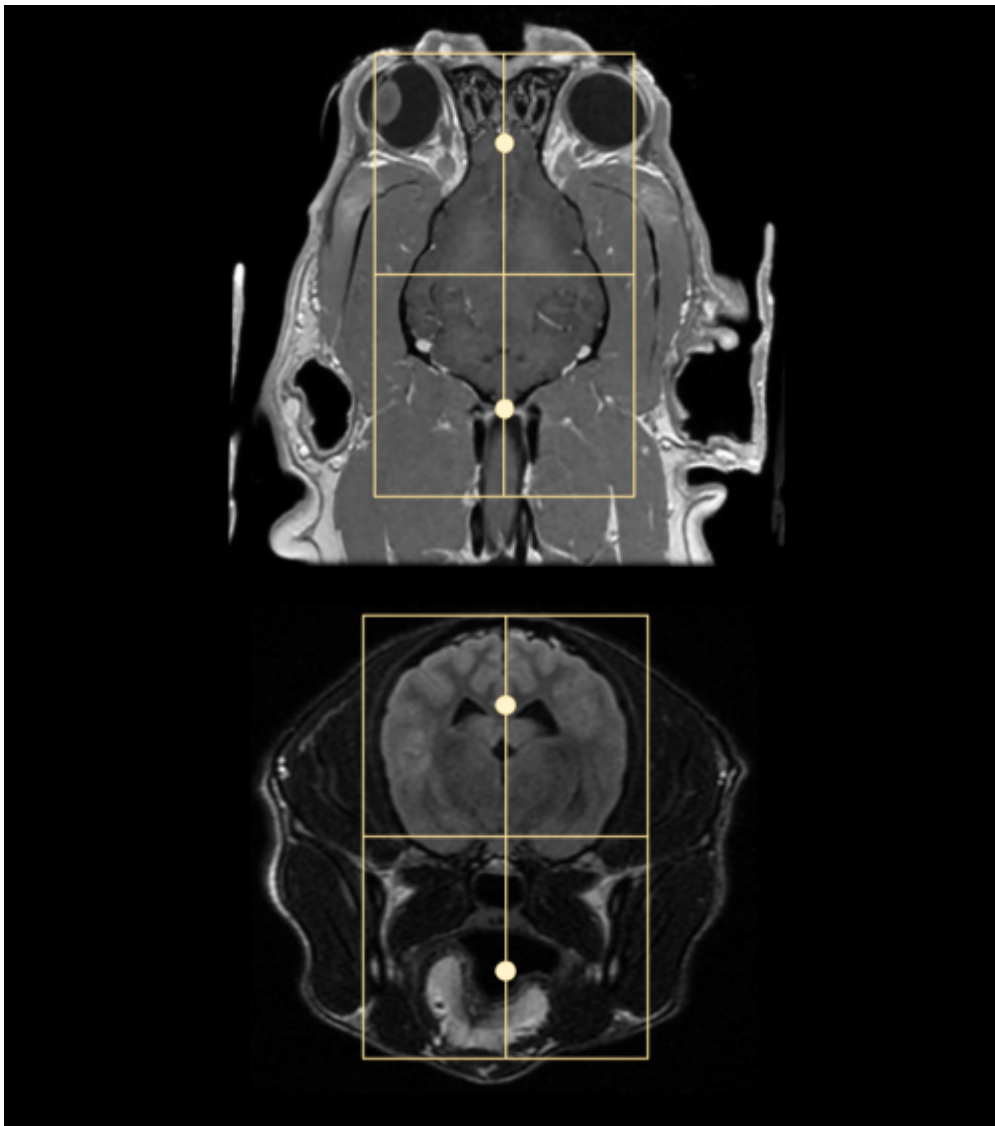


Brain MRI

Scan Coverage and Planning

Sagittal Plane

On the 3 dorsal and axial scout images, plane the slices parallel to the midline of the brain, along the sagittal sinus. On the sagittal scout image, center the FOV on the pituitary gland (noted by the X). resize the FOV to include the orbit to C1/2. Add enough slices to include both orbits. **Be sure to use an odd number of slices to ensure the center slice is at true midline.** If the slice is at true midline, the interthalamic adhesion will be seen as a circle surrounded by CSF.





Axial Plane

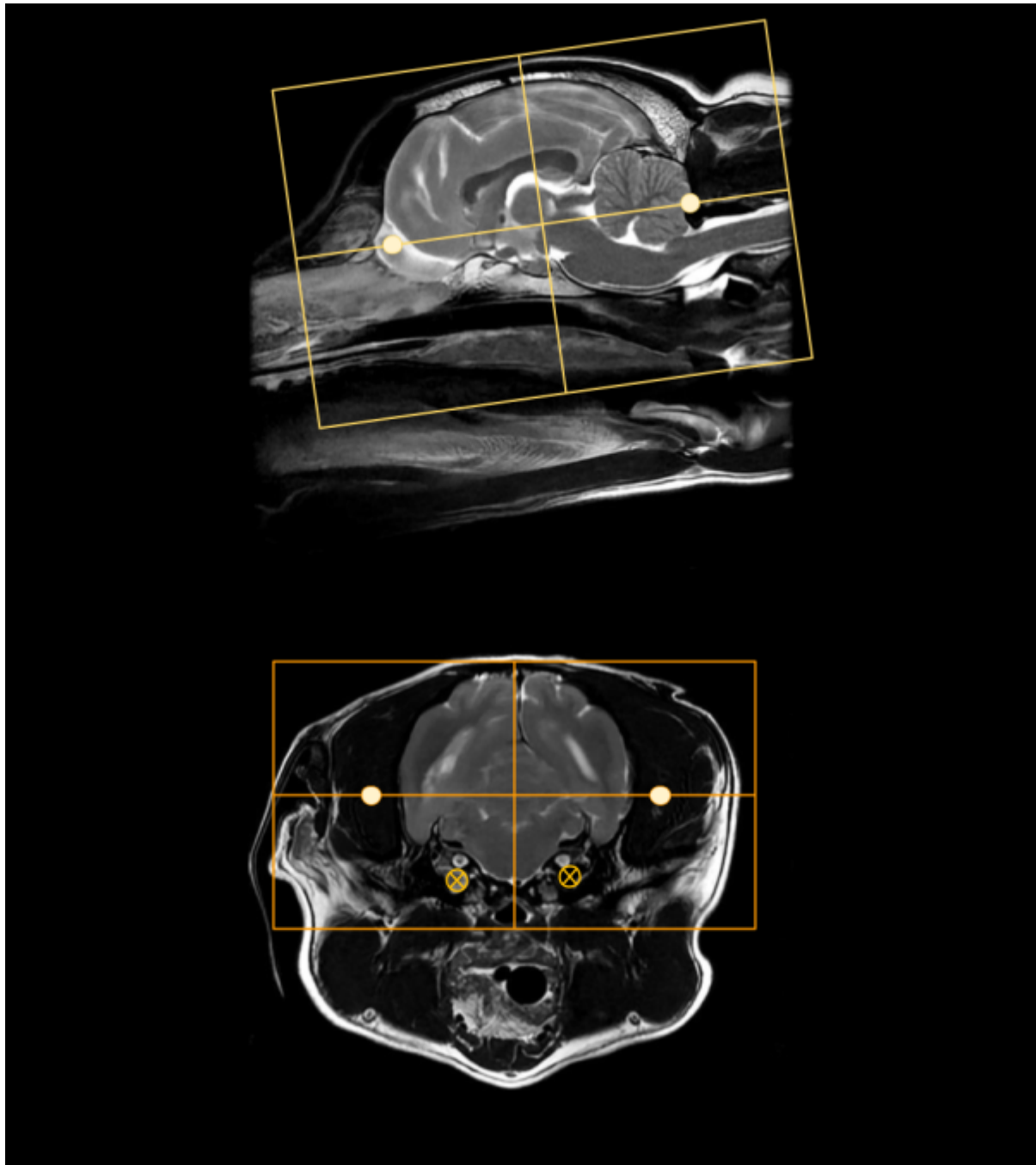
On a true mid sagittal image, place 1 slice in the middle of the interthalamic adhesion, and add enough slices to cover from in front of the olfactory bulb to past the foramen magnum. Angle the slices perpendicular to the hard palate. Check the dorsal and axial images for rotation, and ensure the slices are also perpendicular with the longitudinal fissure of the brain. The FOV is up to clinician preference, but it is good practice to include the entire head, as pathology may be seen in the musculature and in the ears as well as in the brain. Note the muscle atrophy seen on the R side of the post contrast axial image to the right as an example.





Dorsal Plane

On a mid sagittal image, plan slices parallel to the brainstem/cranial spinal cord. There is some anatomic and positional variation with these landmarks, so if neither seems like an appropriate angle, it is also acceptable to plan dorsal slices parallel with the hard palate. The coverage should include at a minimum the bullae to the top of the head. The bullae can be easily located on an axial image, approximately where the facial and vestibulocochlear nerves are visualized. these are marked with small X's on the axial image to the right.



Typical Scan Protocol

The protocol below represents a full brain exam. There is variation depending on the clinical question and clinician preference. The **minimum** recommended sequences are in bold text. Note that some sequences such as the DWI have specific use cases and should be considered required if their indication is present, ie if an ischemic stroke is the clinical question, don't skip the DWI. It is highly suggested to acquire at last one post contrast series with fat saturation.

Sagittal T2

Axial T2

Axial T2*

Axial T2 FLAIR

Axial DWI

Axial T1

Contrast

Sagittal T1

Axial T1

Dorsal T1

Tips and Tricks

DWI in the Brain

Diffusion weighted imaging can be difficult in small animals, especially with older scanners and sequences. There are several steps to take to get the most out of the DWI sequence available on any scanner:

1. **Minimize the TE as much as possible**; this can be done sometimes with reducing the Phase FOV, parallel imaging, or reducing the matrix
2. **Set the Phase direction anterior/posterior**; DWI sequences tend to warp/smear in the phase direction, so this can help keep it at least symmetrical. The DWI sequence is based on an Echo Planar technique which does not include any refocusing pulses, so the longer the sampling time and TE, the more time phase errors have to accumulate and compound. This is especially true with older systems that do not have fast gradients. A/P phase
3. **Shim around the brain**; animals typically have much larger sinuses than humans right next to the brain.

GE Specifics

- Where possible disable dual spin echo, this reduces TE and the dual echo isn't particularly effective
- Where possible, choose the DWI setting 'TETRA'
- ADC MAP process for older scanners: Functool->ADC-> Threshold until only brain is green -> Next -> Compute -> Film/Save -> Multiple locations -> Save as processed images

Siemens Specifics

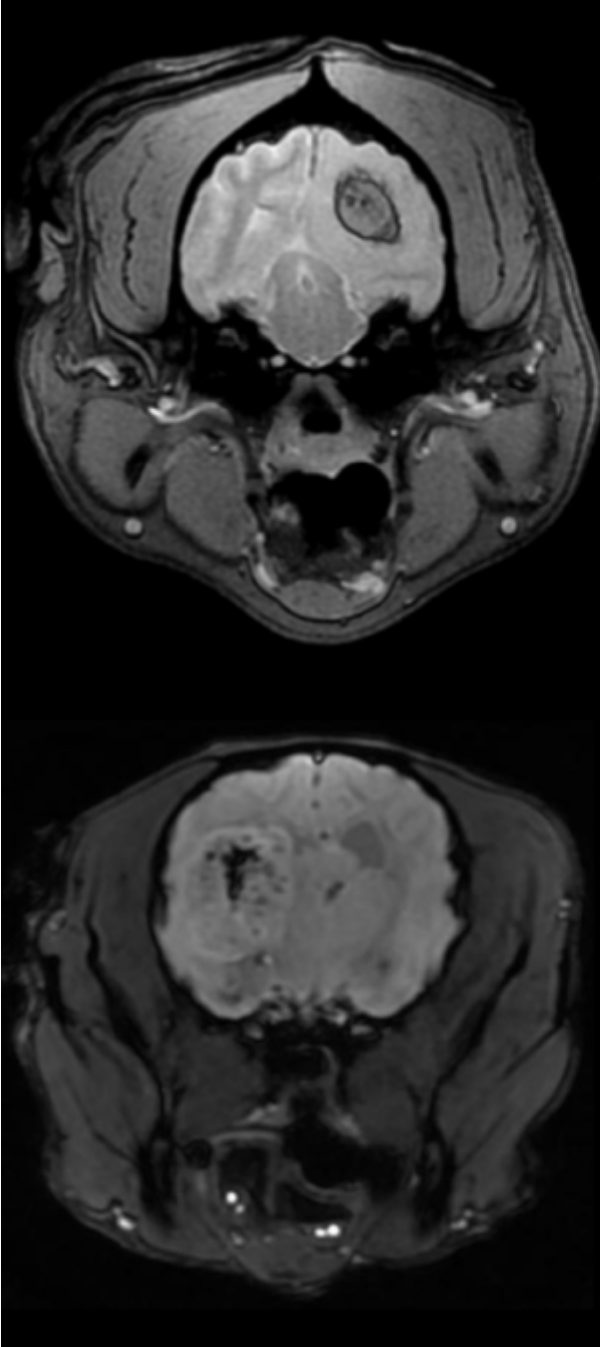
- It can be difficult to acquire diagnostic DWI on small brains with older Siemens scanners, as the smallest FOV possible can be on the order of 180-200mm.
- Try to use a flex coil, or flex + spine coil; this will enable the use of grappa and help with SNR
- Use low resolution; <128, grappa set to 2, and increase averages to 4-8. This may also allow for a smaller FOV.

Sequence Substitutions

With Brain MRI in particular, there are quite a few sequence variations that may be encountered or substituted. These different sequences may provide the same or similar image contrast, but have different SNR, be 3D vs 2D, or have additional special properties. As with all things in MRI, there are trade-offs and pros/cons with each sequence choice that will be noted below. The different sequences will be categorized by their image contrast. Please note that some sequences will be vendor or

software level specific, so may not be available on every scanner.

T2* Contrast



Multi Echo GRE

AKA: MERGE (GE), MEDIC (Siemens), M-FFE (Philips)

Characteristics:

- 2D or 3D
- Gradient Echo
- GRE with multiple TE's

Pros:

- Higher SNR and superior image quality to GRE
- High resolution 3D imaging
- Image hemorrhage in spine
- Anatomic imaging: shoulder and vertebrae

Cons:

- Not available on very old software
- FOV limitations on Siemens scanners

3D Susceptibility Weighted Imaging

AKA: SWAN (GE), SWI (Siemens), SWIp (Philips)

Characteristics:

- 3D
- Flow Compensated Gradient Echo
- Longer TEs; 25-40ms

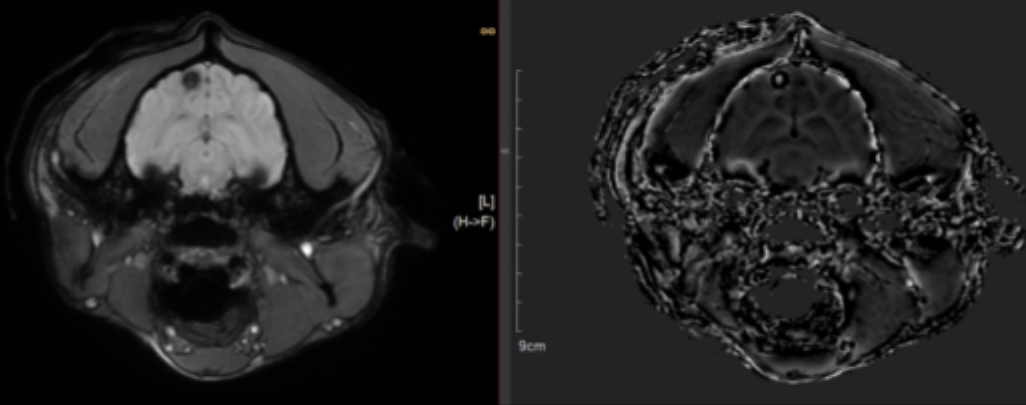
Pros:

- SWI>MEDIC>GRE, most sensitive for hemorrhage
- Newer software: Phase sensitive Image differentiates calcium and hemorrhage
- Black Blood Angiography


Cons:

- Not great for spine imaging
- Phase wrap from large collections of hemosiderin
- Newer software only

Phase Wrap on SWI Phase Image (White in black)



T1 Contrast



Fast Spin Echo

AKA: FSE (GE), TSE (Siemens), TSE (Philips)

Characteristics:


- 2D
- Multiple TE's; Effective TE at k-space center
- Special parameters: echo train length, echo spacing
- Dark grey CSF

Pros:

- High SNR
- Low susceptibility
- Rapid imaging compared to SE
- High sensitivity to Gad

Cons:

- Less grey/white matter differentiation than SE
- Late TE's contribute to image contrast



Fast Spoiled Gradient Echo

AKA: FSPGR (GE), FLASH (Siemens), T1-FFE (Philips)

Characteristics:

- 3D
- Steady state GRE with RF spoiling between TR's
- Very Dark CSF

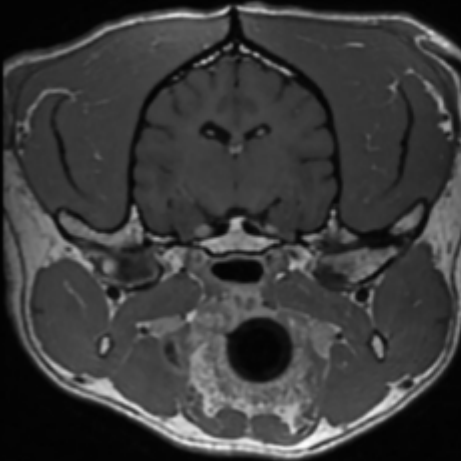
Pros:

- High SNR
- Low susceptibility for GRE
- Isotropic imaging
- Superior Grey/White matter contrast to FSE
- Multiple Fat sat options

Cons:

- Less sensitive to Gad than FSE
- High intravascular signal

}}



3D Fast Spin Echo

AKA: CUBE (GE), SPACE (Siemens), VISTA (Philips)

Characteristics:

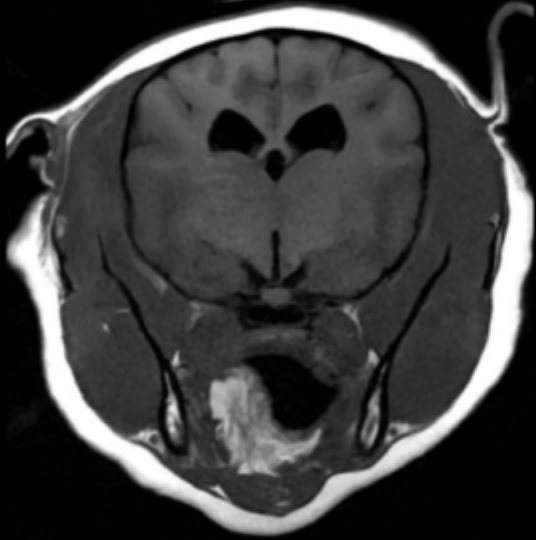
- 3D
- Very Dark CSF
- Different ETL and TE settings for contrasts

Pros:

- High SNR
- High resolution
- Dark intravascular signal post contrast
- Reformats if isotropic

Cons:

- Long run time without parallel imaging
- FOV and scan plane limitations
- Complex contrast behaviors due to long ETL



T1 FLAIR

AKA: T1 FLAIR

Characteristics:

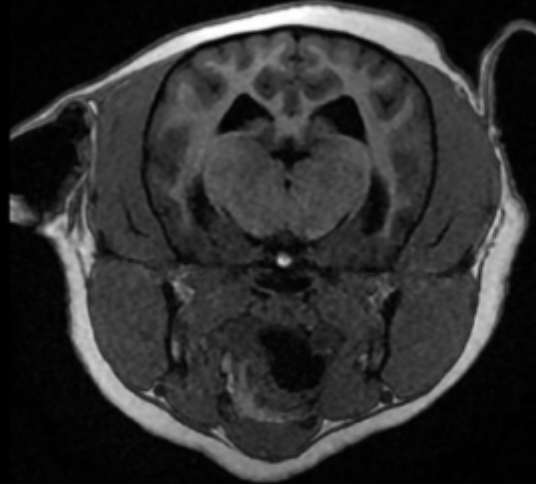
- 2D
- T1 parameter
- Very Dark CSF

Pros:

- Very strong T1 weighting
- Superior Grey/White matter contrast
- Highly Sensitive to Gad
- Greater dynamic range than FSE and FSPGR

Cons:

- Long run time
- Flow and motion artifacts



Inversion Recovery GRE

AKA: BRAVO (GE), MP-RAGE (Siemens), T1-TFE (Philips)

Characteristics:

- 3D
- TI +/- Recovery Time parameters
- Very Dark CSF

Pros:

- Very strong T1 weighting
- Superior Grey/White matter contrast
- Highly Sensitive to Gad
- Greater dynamic range than FSE and FSPGR
- Isotropic Imaging

Cons:

- Long-ish run time
- FOV limitations (Siemens)

From:

<https://wiki.virtual-scan.com/> - Knowledge Portal

Permanent link:

https://wiki.virtual-scan.com/doku.php?id=library:mri_brain&rev=1746462738

Last update: **2025/05/05 16:32**

