

Slice Thickness

What is Slice Thickness?

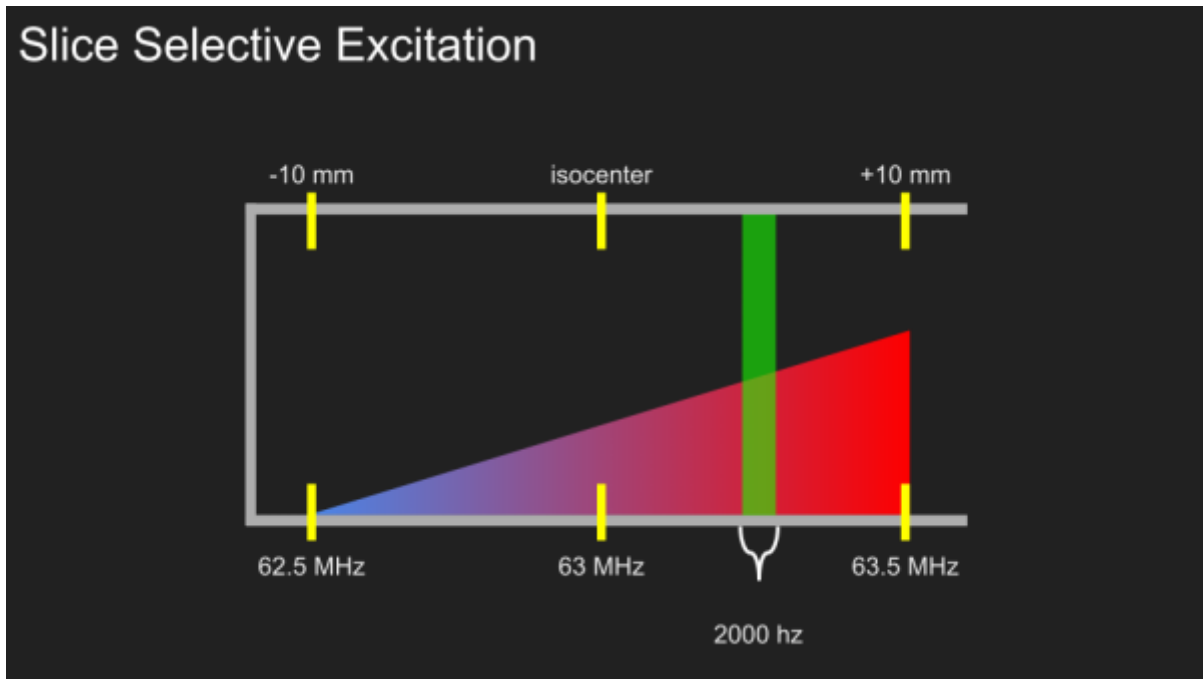
Slice thickness is a user controllable parameter in MRI that must be chosen for every acquisition. A 'slice' in MRI is a planar region of excited tissue, from which signal is recorded and images can be reconstructed. Images are viewed at the scanner, and appear to be perfectly thin 2D pixels cut through anatomy on the monitor, but really represent the summed signals of 'chunks' of tissue called voxels that we can view from different angles. It's a bit unintuitive, but it is important to understand- slice thickness has major impacts on both Signal to Noise Ratio and Volume Averaging artifact.

Slice Selective Excitation

In order to acquire a single slice, a discrete volume of tissue needs to be excited, while leaving any neighboring tissues unaffected so they don't corrupt the signal from the area of interest. The MR scanner achieves this with a combination of gradients and radiofrequency pulses. It is a multi-step process that occurs quickly- on the order of micro to milliseconds. Keeping in mind that once the patient is inside the magnet, some of the protons in their tissues become magnetized and generally align along the b_0 field of the scanner and precess at a known frequency; $\sim 63\text{MHz}$ for 1.5 Tesla or 128 MHz for 3 Tesla.

1. A gradient is imposed perpendicular to the desired slice; this changes the Larmor Frequency along that direction linearly. This is known as the slice select gradient.
2. At the same time as the Slice Select gradient is activated, a radiofrequency pulse will be played out over a few thousand hz, corresponding to the desired slice thickness. This is known as the RF transmit bandwidth.

By modifying either the transmit bandwidth and the strength of the slice select gradient, different slice thickness may be achieved. Typically the transmit bandwidth is not changed much, rather it is the slice select gradient that is primarily used to determine slice thickness. In the example below, a 2000 hz range of frequencies between 63 and 63.5 MHz is transmitted while a gradient is turned on, exciting a slice of tissue (green) a little above isocenter; in this process both the slice thickness and location are determined by the RF and gradient combination.



Slice Thickness in 2D and 3D imaging

Most veterinary imaging is done in 2D mode, meaning that each slice is excited and encoded separately from the other slices, and all signal generated will be from within that slice volume. This, among other pulse sequence factors, inherently limits how thin a slice can be achieved in a reasonable amount of time. For most purposes, a 2mm slice is as thin as is practically possible for a 2D sequence. For slices thinner than 2mm where typical slice coverage is required, a sequence in 3D mode will be required.

Unlike 2D imaging, a sequence in 3D mode will excite a whole volume of tissue and then differentiate slices with an additional slice encoding gradient, resulting in a much more efficient SNR per slice. This adds a useful property to 3D imaging: More slices coverage = more SNR. If thin slices are needed with 3D imaging, more slices can be added to increase SNR and improve image quality at the cost of additional imaging time. Conversely, and importantly, reducing slice number will reduce SNR, so be sure when scanning to be careful when adjusting slice coverage with 3D sequences, or to account for the SNR loss with additional parameter changes.

How to Use Slice Thickness

As mentioned earlier, slice thickness is a major controller of Signal to Noise Ratio and of the volume averaging artifact. So what is the appropriate slice thickness to choose for any given situation? It depends, but there are some rough guidelines. Generally, the slice thickness should be chosen to at least match the expected size of the smallest pathology of interest and the anatomy to be imaged. Once that has been determined, other factors controlling SNR such as bandwidth, resolution, and averages/NEX should be modified maintain appropriate signal. Below are some suggested slice thicknesses for different scenarios:

Spine Imaging, Sagittal Plane:

- Extra small (<10lbs): 2mm
- Small (10-20lbs): 2.5mm

- Medium (20-40lbs) 3mm
- Large (40+lbs) 3-3.5mm

Spine Imaging Axial Plane:

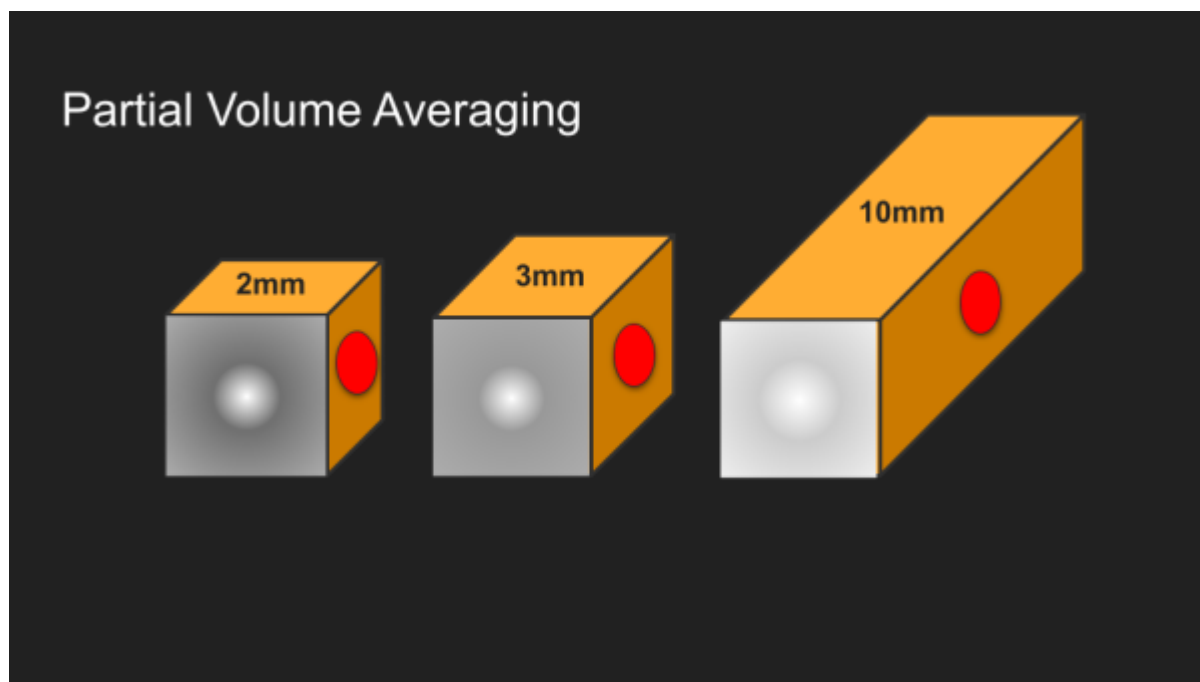
- Extra Small (<10lbs): 2.5mm
- Small (10-20lbs): 3mm
- Medium (20-40lbs): 3mm
- Large (40-100lbs): 3.5mm
- Extra Large (100+ lbs): 4mm

Brain Imaging, All Planes:

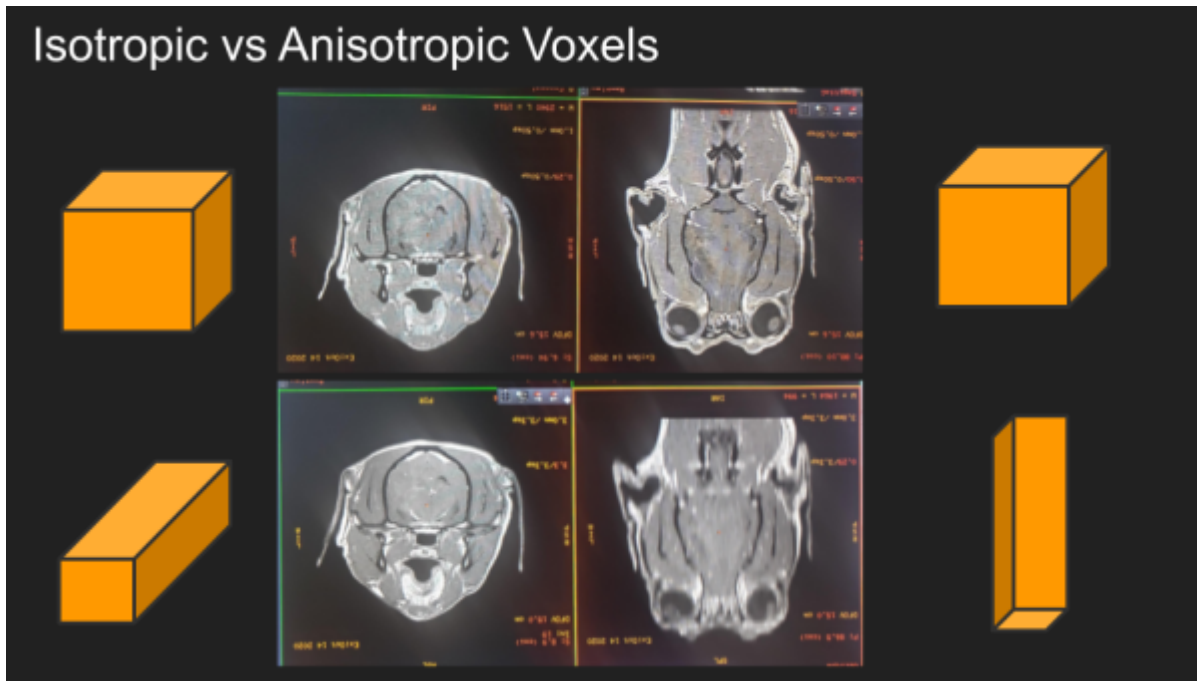
- Extra Small (<10lbs): 2.5mm
- Small (10-20lbs): 3mm
- Medium (20-40lbs) 3mm
- Large (40+lbs): 3.5mm

Examples of Slice Thickness Effects


In the example slide below, notice the 'depth' of the voxel affects how the 'lesion' appears on the side of the voxel that we view on our monitors.



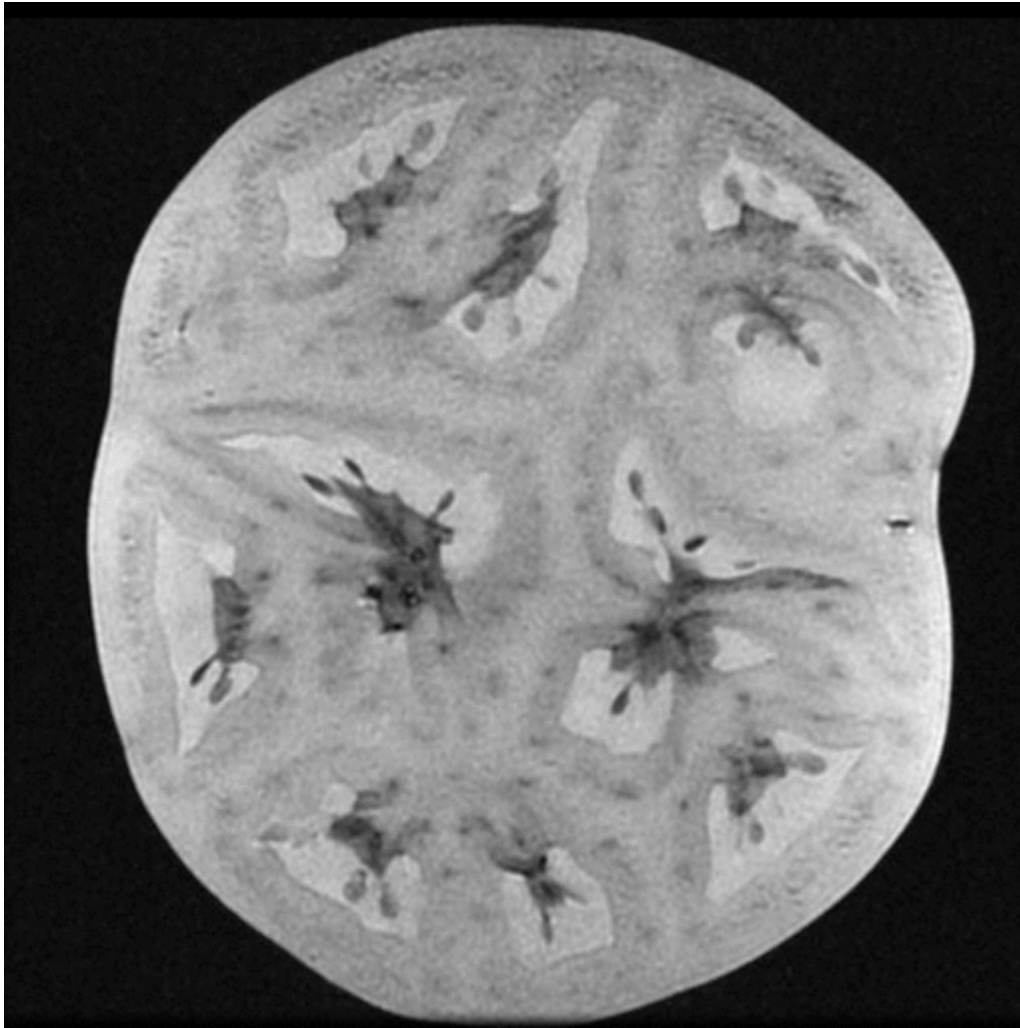
In the example below are two 3D acquisitions side by side; notice the difference between the dorsal reconstructions; one has been acquired with a perfectly cubic voxel, and the other has been acquired with a slice thickness comparable to a 2D acquisition.



In the example below, notice the changes between the two acquisitions; the thicker slice has higher SNR, but the 'GE' symbol has material from the front and back averaged in, and the slice thickness ramp is thicker.



Below is a GIF of slice thickness being changed from 1mm to 15mm thick in a slice of tomato.



From:
<https://wiki.virtual-scan.com/> - **Knowledge Portal**

Permanent link:
https://wiki.virtual-scan.com/doku.php?id=library:slice_thickness&rev=1779805488

Last update: **2026/05/26 14:24**

