

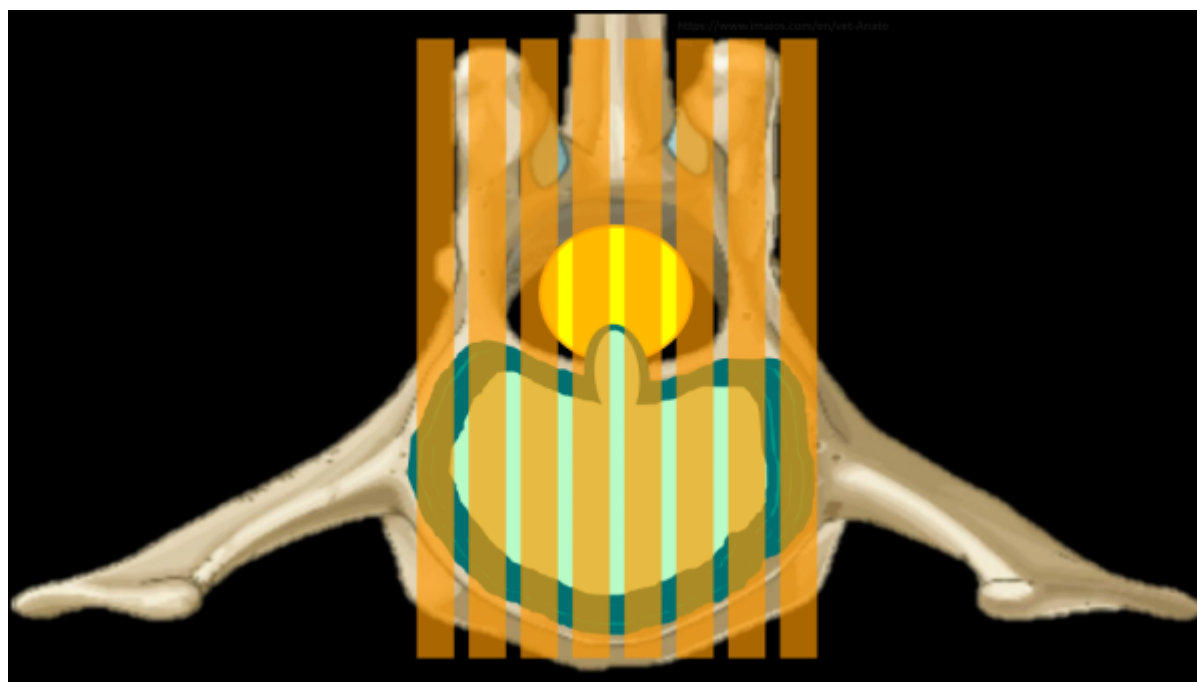
# Spine MRI Deep Dive

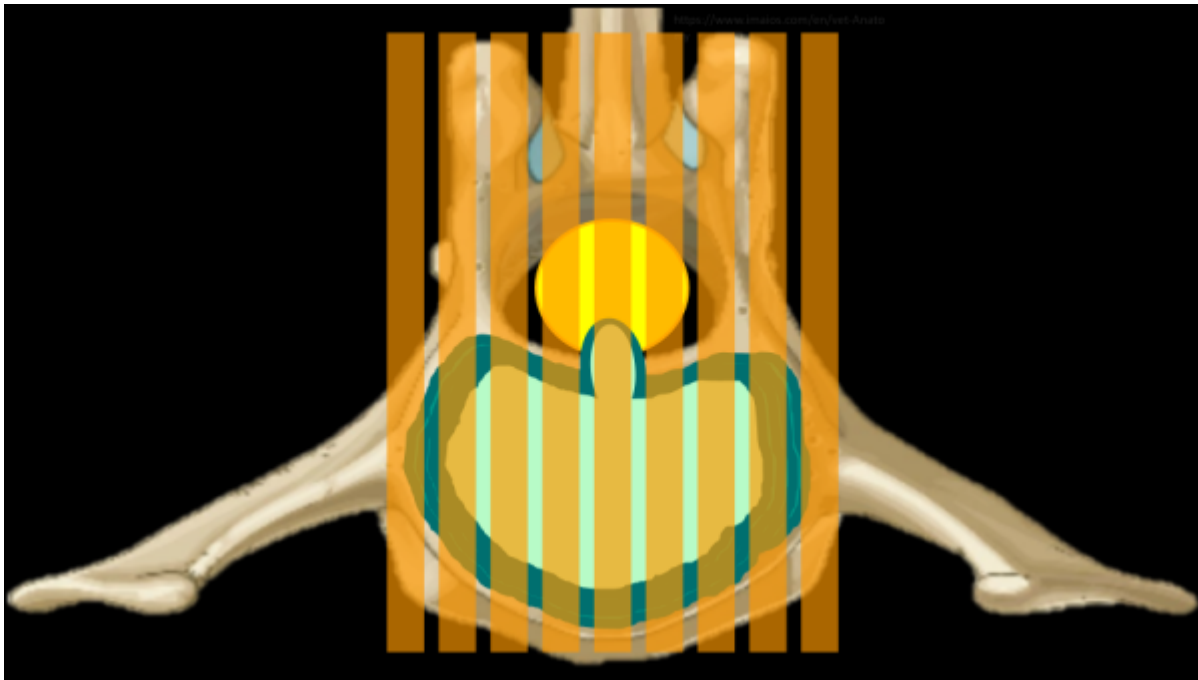
## What is this page?

This page is dedicated to more technical information regarding spine imaging, to include anatomy, MRI technique, pathology, and more of the 'why' of spine MRI. This page will follow the format of a question and answer dialogue for each topic.

## Why is it important to use an odd number of slices for sagittal spine imaging?

Using an odd number of slices while planning out a mid sagittal slice ensures that the center is 'True' mid sagittal. This also makes it so that the slices on either side of the mid sag slice are a symmetrical distance away from midline. Canine and feline anatomy is so much smaller than humans that, even with a 2-3mm slice thickness, only 3-ish slices visualize the spinal cord well. Considering that each slice will have some degree of partial volume averaging, it is crucially important that the center slice is accurate. Consider the case of a mid-line disc extrusion in the images below; which series of slices will best image the disc? The even numbered series will place a slice on either side of the most compressive part of the extruded disc.



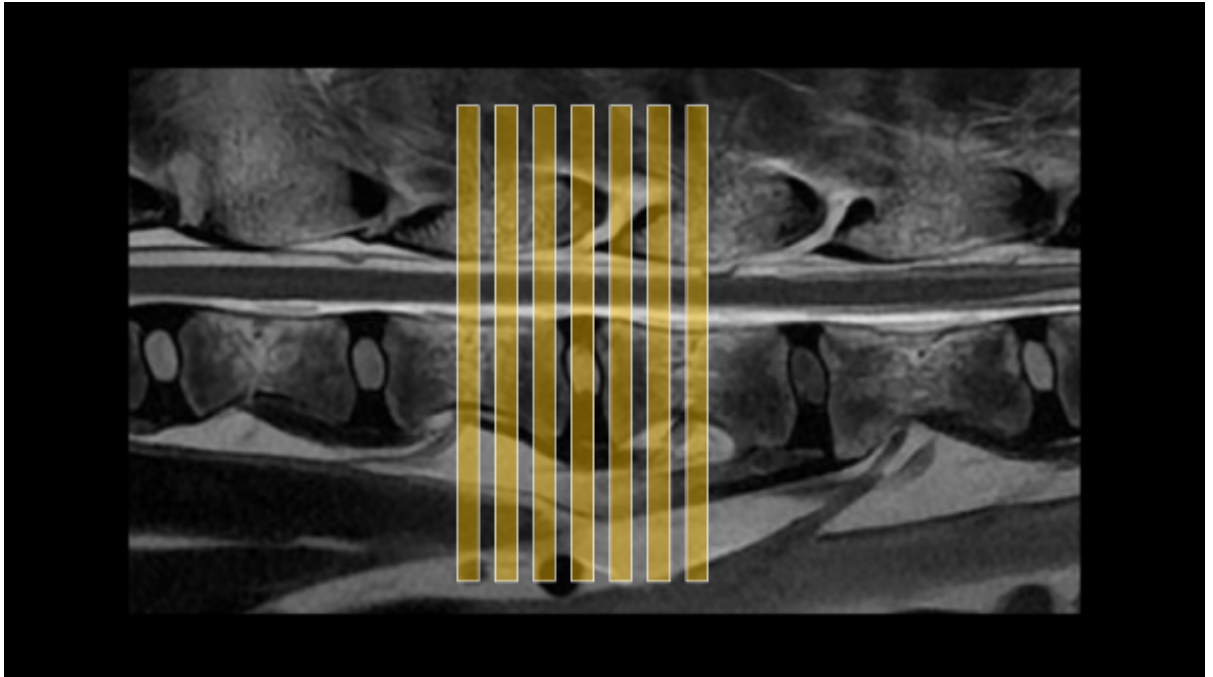


### **How do I communicate which disc space I'm looking at?**

There is some common nomenclature to be familiar with when it comes to communicating with other imagers about which bit of anatomy is being scanned. By convention, each vertebrae will be described by which section of the spine it's in and it's corresponding number in that section, ie the 4th lumbar vertebrae will be L4. The discs are described by the vertebrae on either side, ie the disc between the 4th and 5th Lumbar vertebrae is L4/5. If there are multiple discs in the area of concern, it may be described by the first and last vertebrae if it's contiguous: T12-L3 would mean each disc between T12 and L3 should be scanned. This may also be communicated like T12/13/1/2/3. Importantly, this relies on knowing that 13/1 is the junction of the thoracic and lumbar spines, and most patients will have 7 Lumbar vertebrae and 13 thoracic vertebrae.

### **How many axial slices should I use for each disc space?**

There is some variation depending on the slice thickness and the size of the animal, but a general guideline would be to use 3-7, erring on the side of 7 if time allows. For most canine and feline patients, 7 slices at 3mm thick, centered on the disc, will cover from mid-body to mid-body on the vertebrae to either side of the disc. This extra coverage is good to have, as extruded disc material is not always completely visualized on sagittal images, and not always confined to just the space above the disc. Often, disc material can be found cranially or caudally to the origin, and even into the foramina laterally. Additionally, there are veins in the middle of the spinal cord on the ventral side along it's entire length; these can be damaged and result in hemorrhage that may also travel some distance from the disc.



From:  
<https://wiki.virtual-scan.com/> - **Knowledge Portal**

Permanent link:  
[https://wiki.virtual-scan.com/doku.php?id=library:spine\\_deep\\_dive&rev=1742255927](https://wiki.virtual-scan.com/doku.php?id=library:spine_deep_dive&rev=1742255927)

Last update: **2025/03/17 23:58**

