

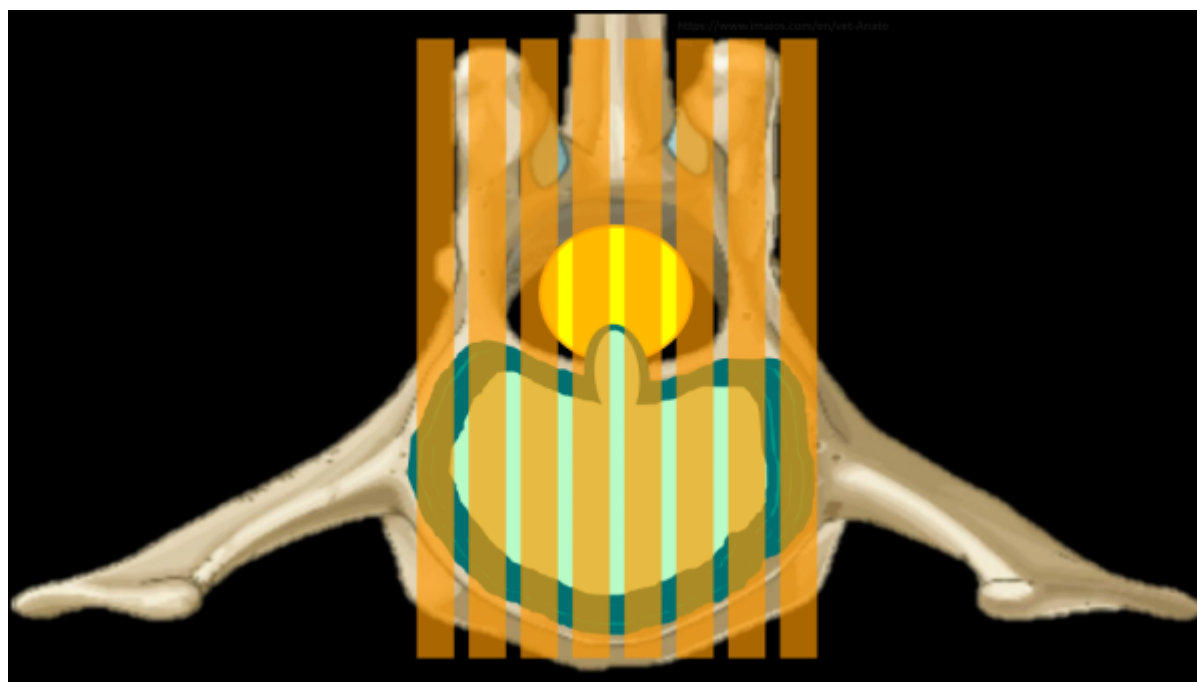
Spine MRI Deep Dive

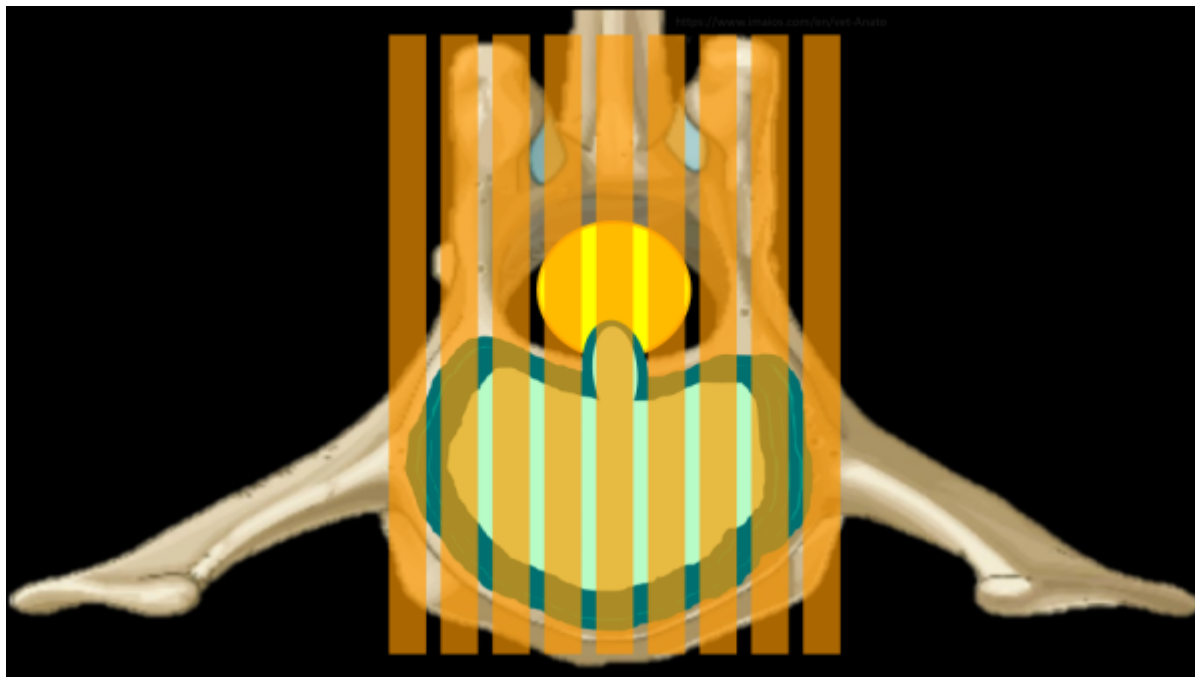
What is this page?

This page is dedicated to more technical information regarding spine imaging, to include anatomy, MRI technique, pathology, and more of the 'why' of spine MRI. This page will follow the format of a question and answer dialogue for each topic.

Why is it important to use an odd number of slices for sagittal spine imaging?

Using an odd number of slices while planning out a mid sagittal slice ensures that the center is 'True' mid sagittal. This also makes it so that the slices on either side of the mid sag slice are a symmetrical distance away from midline. Canine and feline anatomy is so much smaller than humans that, even with a 2-3mm slice thickness, only 3-ish slices visualize the spinal cord well. Considering that each slice will have some degree of partial volume averaging, it is crucially important that the center slice is accurate. Consider the case of a mid-line disc extrusion in the images below; which series of slices will best image the disc? The even numbered series will place a slice on either side of the most compressive part of the extruded disc.



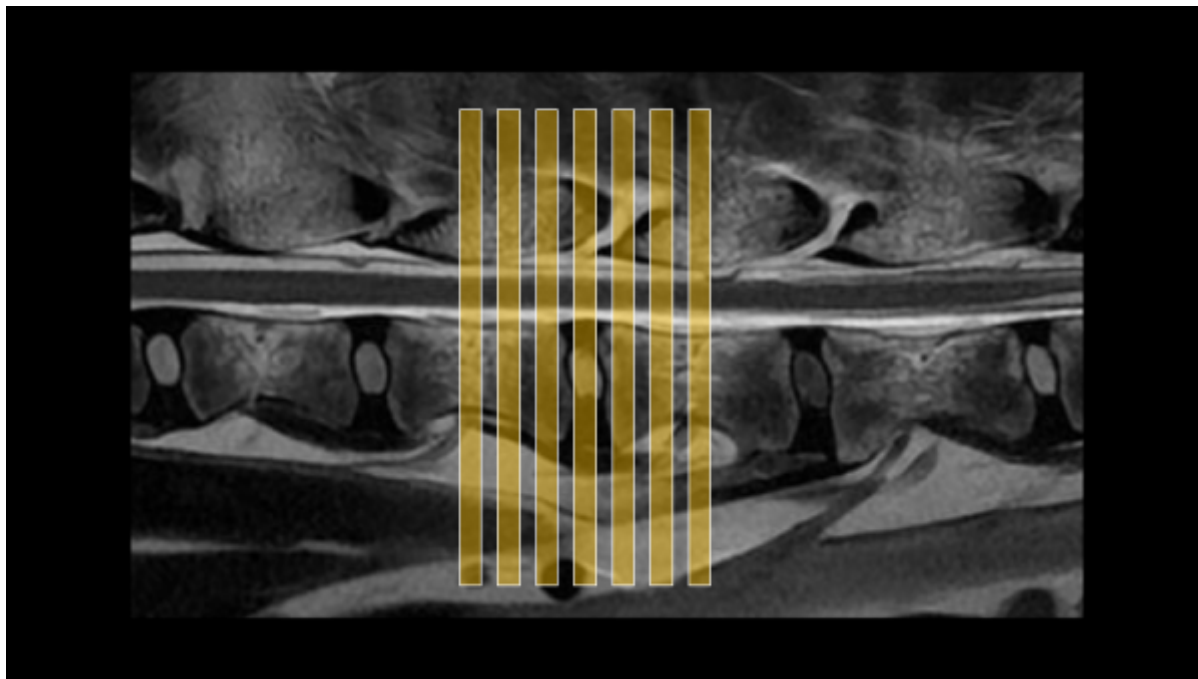


How do I communicate which disc space I'm looking at?

There is some common nomenclature to be familiar with when it comes to communicating with other imagers about which bit of anatomy is being scanned. By convention, each vertebrae will be described by which section of the spine it's in and it's corresponding number in that section, ie the 4th lumbar vertebrae will be L4. The discs are described by the vertebrae on either side, ie the disc between the 4th and 5th Lumbar vertebrae is L4/5. If there are multiple discs in the area of concern, it may be described by the first and last vertebrae if it's contiguous: T12-L3 would mean each disc between T12 and L3 should be scanned. This may also be communicated like T12/13/1/2/3. Importantly, this relies on knowing that 13/1 is the junction of the thoracic and lumbar spines, and most patients will have 7 Lumbar vertebrae and 13 thoracic vertebrae.

How many axial slices should I use for each disc space?

There is some variation depending on the slice thickness and the size of the animal, but a general guideline would be to use 3-7, erring on the side of 7 if time allows. For most canine and feline patients, 7 slices at 3mm thick, centered on the disc, will cover from mid-body to mid-body on the vertebrae to either side of the disc. This extra coverage is good to have, as extruded disc material is not always completely visualized on sagittal images, and not always confined to just the space above the disc. Often, disc material can be found cranially or caudally to the origin, and even into the foramina laterally. Additionally, there are veins in the middle of the spinal cord on the ventral side along it's entire length; these can be damaged and result in hemorrhage that may also travel some distance from the disc.



There's a microchip causing artifact on my image, is it safe and what can I do?

Most RFID tracking chips used in pets contain a small iron core which can cause substantial artifact, especially in small animals. While there isn't much literature, it is good to note that these implants do appear safe and are well encapsulated in fibrous tissue, so the risk of movement and heating are quite low. To manage the artifact, there are several things to do if there isn't a metal suppression sequence:

1. Use a fast spin echo sequence
2. Increase bandwidth (<1 pixel chem shift, <10 ms echo spacing)
3. Decrease slice thickness
4. Increase in-plane resolution a bit
5. The artifact will smear out in the frequency encoding direction, consider swapping
6. Increase averages/NEX, as all of the above parameter changes will reduce SNR

The susceptibility artifact evolves over time throughout the frequency encoding period. Increasing the bandwidth helps by reducing the echo spacing so that the time between data points is shorter. This also reduces the time between strong refocusing pulses in the FSE sequence, further suppressing the artifact. In addition, the amplitude of the frequency encoding gradient is increased, which also helps to reduce the severity of the artifact. Similar ends are achieved by increasing the imaging matrix and reducing the slice thickness; it will impose stronger gradients onto the microchip. Swapping the frequency encoding direction won't suppress the artifact, but it will redirect it or change the shape of it, depending on the orientation of the microchip. All of these parameter changes are likely to increase scan time, but it is best to avoid using parallel imaging if the artifact is significant, as it may cause it to show up centrally in the image.

I have to cover a large area with an axial slices, what is the best way to do it?

I need thinner slices! What can I do?

When imaging very small anatomy with 2D FSE sequences, it can be difficult to reduce slice thickness to much less than 2mm without sacrificing too much scan time or SNR. If less than 2mm imaging is required, it is necessary to move to a 3D sequence. Any time this is done, it is a good idea to discuss with the clinician the caveats for whichever sequence is being substituted. Before substituting, consider the following questions:

- What is the goal of this sequence? Am I trying to demonstrate contrast enhancement, or show anatomical information?
- Is true T2 weighting required or is bright fluid contrast good enough?
- What are the drawbacks to this sequence? Are there any particular artifacts, contrast behaviors, or scan time limitations?
- What is the inherent SNR of the sequence?
- What are the specific advantages of this sequence?

Below are some commonly available sequences, with their vendor specific names, where to find them, caveats, and advantages:

Balanced Steady State Free Precession with Phase Cycling (FIESTA-C, CISS)

Where to find: Most vendors have this saved in an IAC protocol, occasionally spine.

Caveats: T2/T1 weighting leads to unusual contrast behaviors; fluid will be very bright, edema won't be well demonstrated, will show gad enhancement. Out of the box this is typically saved with an out of phase TE, be sure to swap it to in-phase. Phase cycling will greatly reduce off-resonance artifact but it can still be present around microchips and large FOV/slice coverage. Bone signal is dark-ish which can occasionally obscure anatomical information. Be sure to adjust bandwidth for the lowest TR

Advantages: Very high inherent SNR; it's possible to get really high resolution or very thin slices. It can be run isotropically for reformats. Bright fluid contrast can help with anatomic information

RF Spoiled Fast Gradient Echo (FLASH, FSPGR)

Where to find: Most vendors have this saved in a brain protocol

Caveats: Vessel signal will be bright, especially after contrast. These sequences are less sensitive to gadolinium enhancement than FSE. Be aware that susceptibility/dephasing artifacts can still be present from hemorrhage and inhomogeneity. Check the flip angle out of the box, 12-15 degrees is a good range. Be sure to keep the bandwidth relatively high to reduce blurring. Be sure to swap TE to in-phase.

Advantages: Pretty robust sequences with relatively high inherent SNR. There are usually different fat saturation options available such as SPECIAL/SPAIR which can be more homogenous and less time intensive than regular FatSat options. The grey/white matter contrast is superior to FSE

RF Spoiled Fast Gradient Echo with k space modifications (LAVA, VIBE)

Where to find: Most vendors have this saved in a routine liver protocol

Caveats: Vessel signal will be bright, especially after contrast. These sequences are less sensitive to gadolinium enhancement than even the FSPGR/FLASH. Be aware that susceptibility/dephasing artifacts can still be present from hemorrhage and inhomogeneity. These are not typically very useful for imaging the spinal cord or other very small anatomy, and the bone signal can be mottled. These are often pre-saved or require some fat saturation, and TE may not be selectable. The non-linear kspace trajectory will affect image contrast. Flip angles may be as low as 5-8 degrees.

Advantages: These are really designed to run for speed more than anything else, so they'll be faster than the FSPGR/FLASH. Reserve this for something incidental in the soft tissues outside the spine.

3D Fast Spin Echo (CUBE, SPACE)

Where to find: Most vendors have this saved in a spine or brain protocol

Caveats: These sequences have been around for awhile, but only effectively executed more recently on modern scanners with faster gradients, so keep in mind how old the scanner is; often a 3D GRE will be less blurry on older scanners. There are going to be multiple contrasts to choose from, it is best to select one out of the box that is closest to the same body part and contrast that is needed, as modifying parameters to change contrasts may be a lot of work and result in errors. There may be coil combination, FOV, or direction limitations. Due to long run times, parallel imaging will be required. For very small anatomy these sequences can still end up looking blurry, it is best to reduce the ETL/Turbo factor from the out of the box parameters and leave the bandwidth relatively high and make up time with parallel imaging. Because of the very long ETL/Turbo factor and varying flip angles, the contrast behaviors will be a bit different from a 2D FSE.

Advantages: Very high SNR, these can be run isotropically or with very thin slices. Due to the long ETL and varying flip angle intravascular signal will be dark, which is excellent for vessel wall imaging ruling out vessel vs. lesion. True T2 weighting can be achieved with a higher TE ~120, though keep the ETL a bit shorter than the out of the box parameters. If using a STIR, consider running it post contrast! This will suppress intravascular signal and help visualize nerves.

Multi Echo GRE (MERGE, MEDIC)

Where to find: Most vendors have this saved in a cervical spine protocol

Caveats: Relatively lower SNR for 3D sequences, may have a bit of a longer run time. Sensitive to motion artifact, so carefully consider the phase encoding direction when scanning; axial in the thoracic spine is often low image quality. Suggested planes: Cervical Spine: Axial or sagittal Thoracic Spine: Sagittal or Dorsal, Lumbar Spine: Any plane should look ok. isotropic imaging will run very long, so it's not usually worth it since parallel imaging will decrease the already lower SNR. Best to run with slice thickness 1.5mm or greater. May have an FOV limitation depending on software level.

Advantages: Much more robust T2* contrast due to multiple combined echoes at both short and long TE's. Great anatomic contrast for the spine as bone will be black, discs and joints will be very bright, CSF and Fat are different shades of grey, and grey/white matter contrast is excellent. Sensitive to hemorrhage around the spinal cord. Hydrated disc extrusions can be more apparent than on T2. Can have multiple fat saturation options such as SPECIAL, SPAIR, Water Excitation, as well as regular Fatsat. Can be great for a wobbler's case.

From:
<https://wiki.virtual-scan.com/> - **Knowledge Portal**

Permanent link:
https://wiki.virtual-scan.com/doku.php?id=library:spine_deep_dive&rev=1750087676

Last update: **2025/06/16 15:27**

