

Other Spine Diseases

Other Diseases of the Spine

There is more to spine pathology than just IVDD! On this page, there will be case examples of non-IVDD pathology in the spine, and a list of any useful sequences.

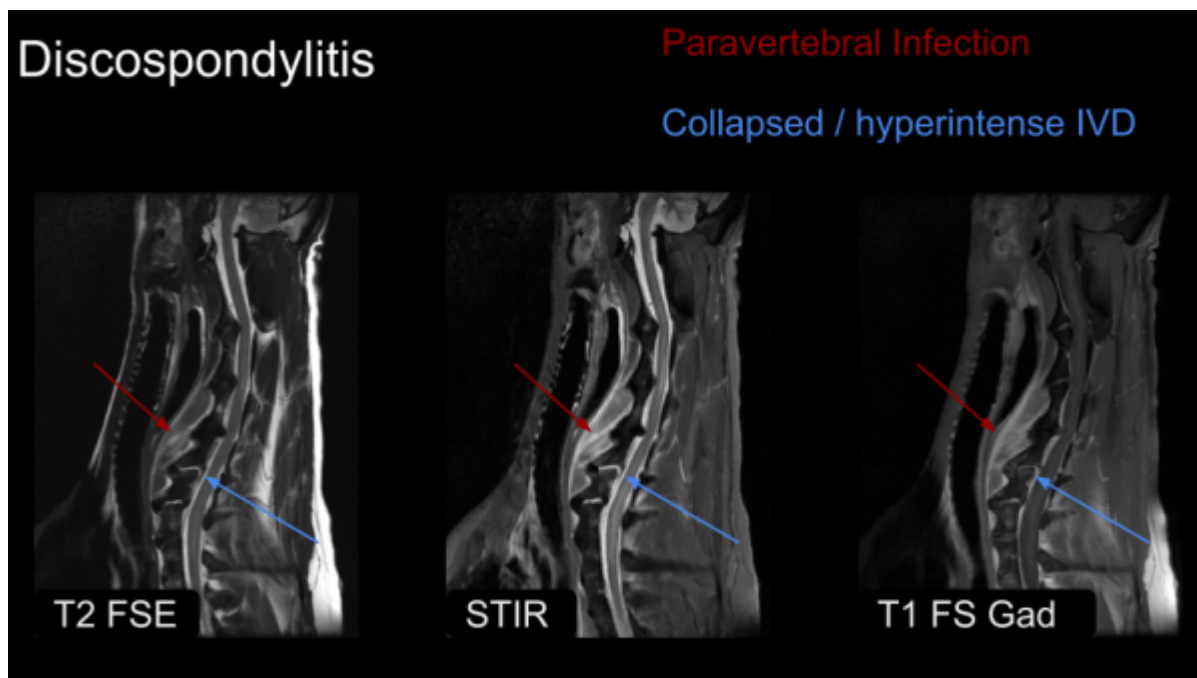
Discospondylitis

Discospondylitis is an infection of the vertebral endplates and intervertebral disc, most commonly of bacterial origin. Some notable features are:

- Collapse of the IVD
- STIR/T2 hyperintensity
- Contrast enhancement
- Paravertebral inflammation or fluid like collections
- sclerotic changes to vertebrae

Useful sequences:

- STIR
- T1 with and without fat saturation
- T1 post contrast with fat saturation



Arachnoid Diverticulum

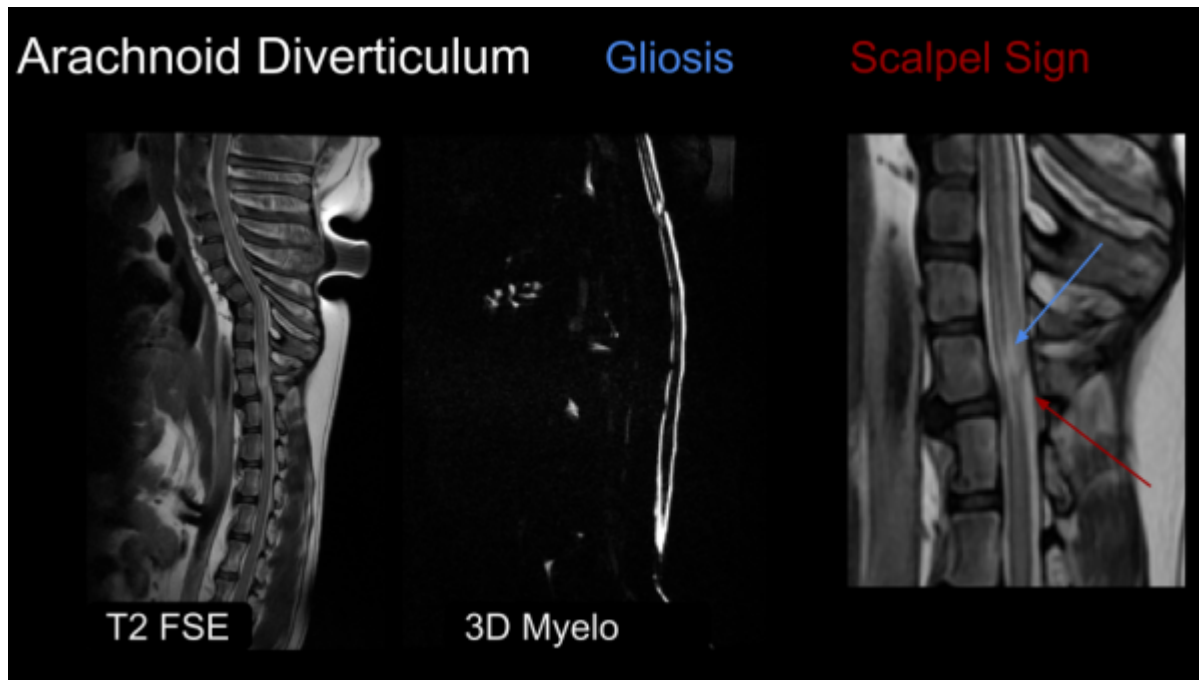
Some notable features of arachnoid diverticulum:

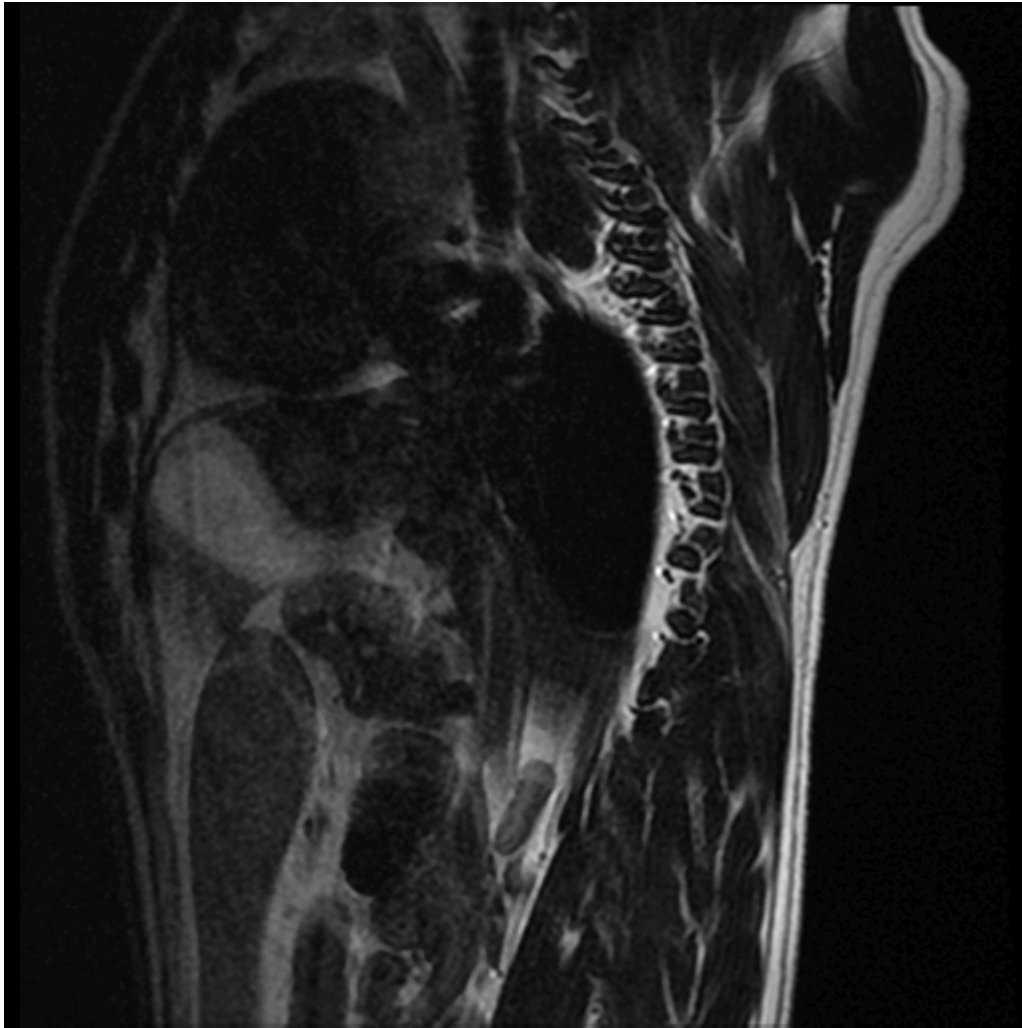
- Scalpel sign

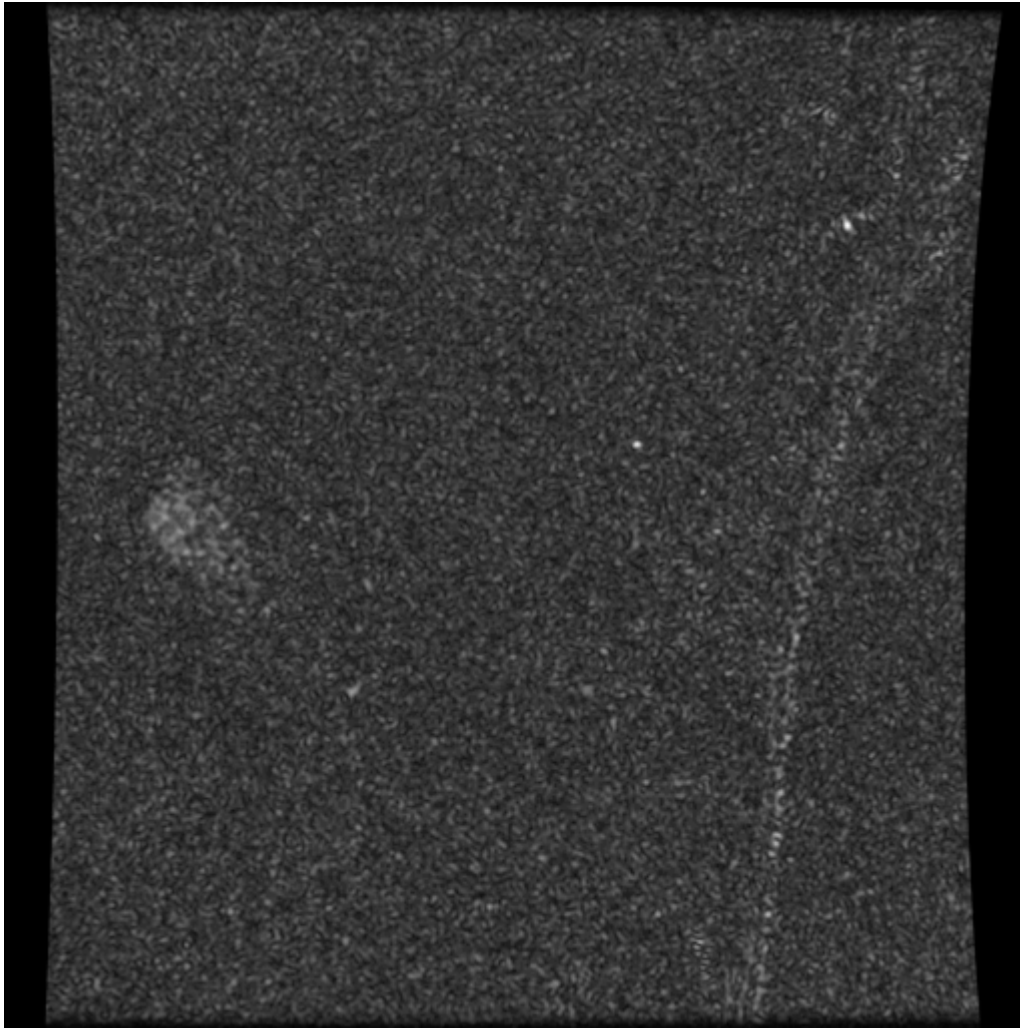
- Gliosis
- Lesion demonstrates CSF signal characteristics

Useful Sequences:

- 3D Myelogram
- 3D FIESTA-C / CISS
- Sag T2 FSE







From:
<https://wiki.virtual-scan.com/> - **Knowledge Portal**

Permanent link:
<https://wiki.virtual-scan.com/doku.php?id=otherspinediseases&rev=1781282845>

Last update: **2026/06/12 16:47**

