

Plexus Pathology

Plexus Pathology

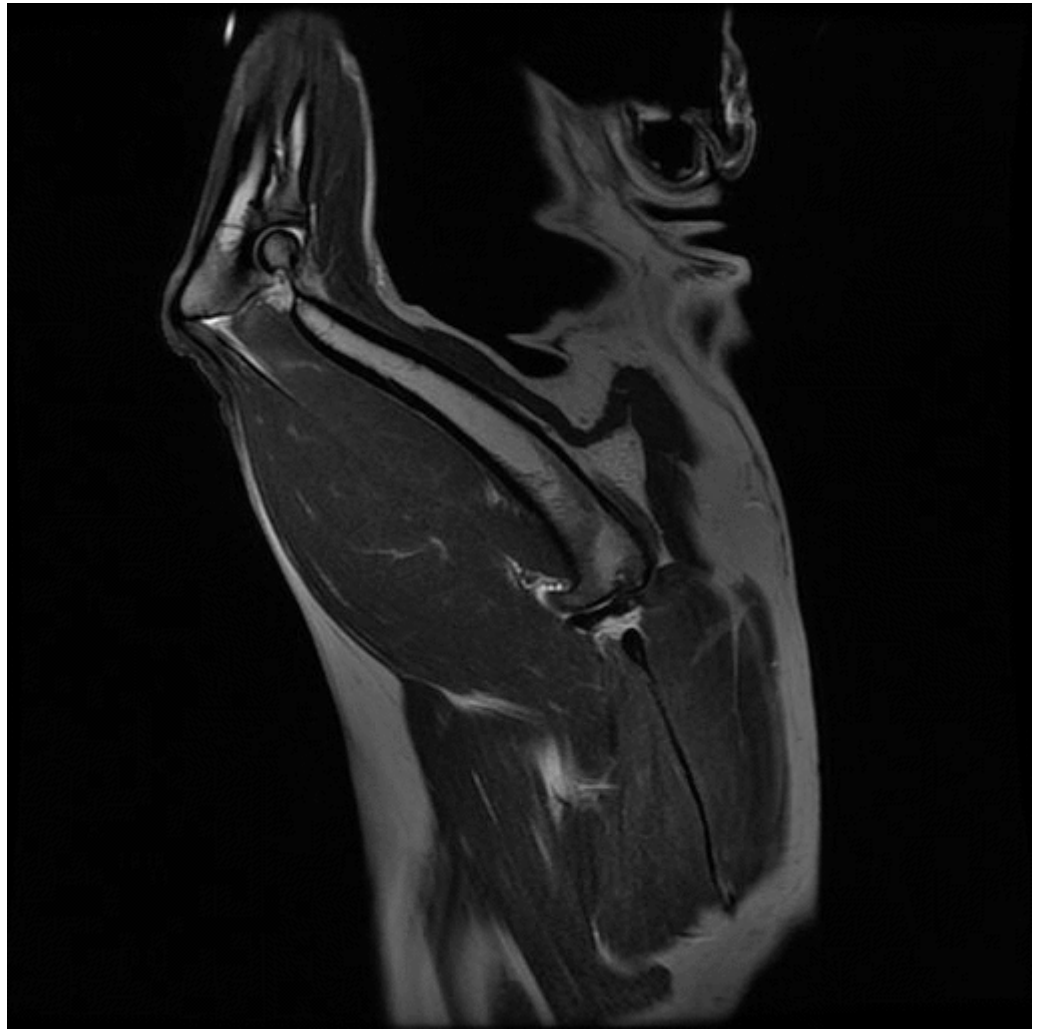
Locating pathology in either the brachial or lumbar plexus can be difficult; the nerves are small, have tortuous routes, extend far into the limbs, and run parallel to veins and arteries. In the case of the brachial plexus, there is also respiratory motion and ventral location to consider. An imaging approach appropriate for these pathologies is described in the [Brachial Plexus MRI Tips and Tricks](#) section. The more common pathology to be found in either plexus is the Peripheral Nerve Sheath Tumor (PNST); the brachial plexus is more commonly affected than the lumbar plexus. There is some variability in the appearance of PNST's, it could be a discrete or large lesion, or could appear as thickened and enhancing nerves. Lesions can occur at any point along the nerve, but are generally categorized by location:

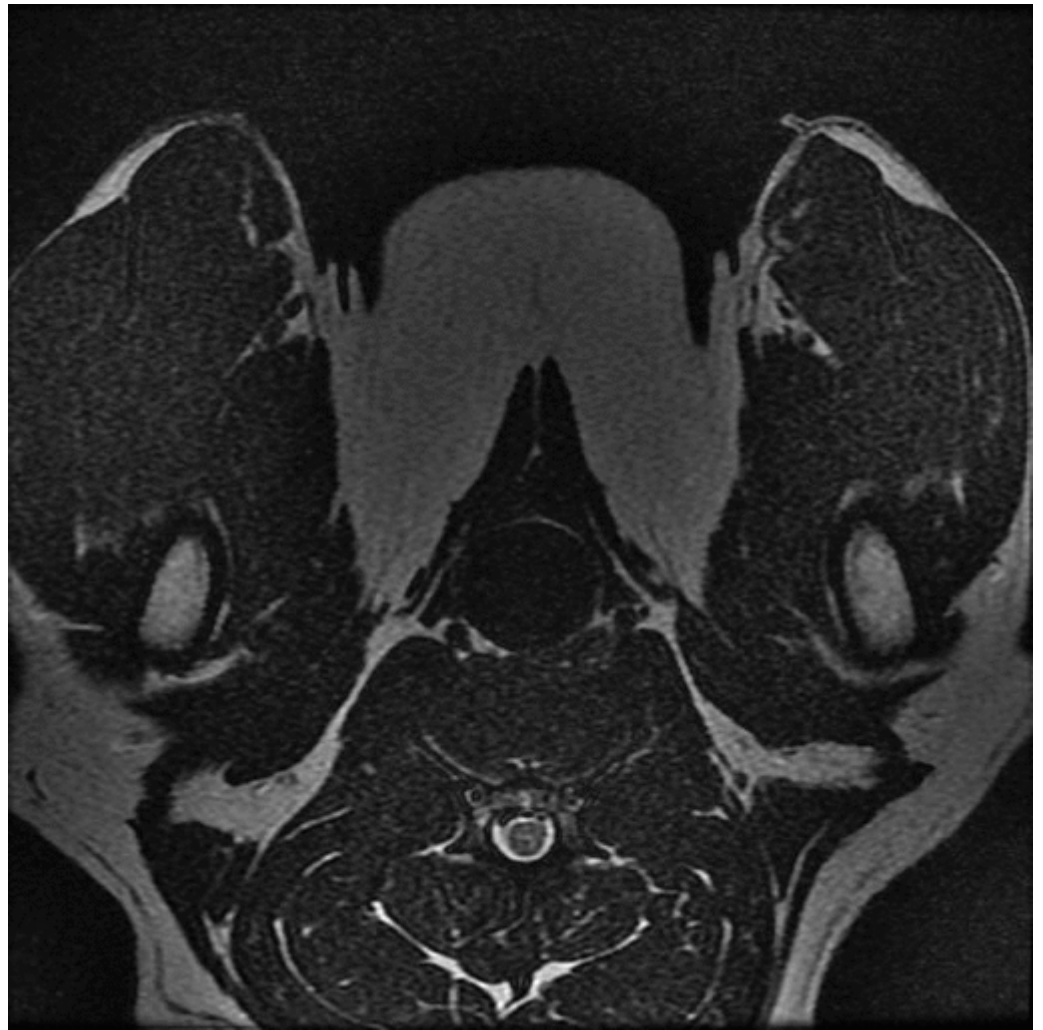
- Root
- Plexus
- Peripheral

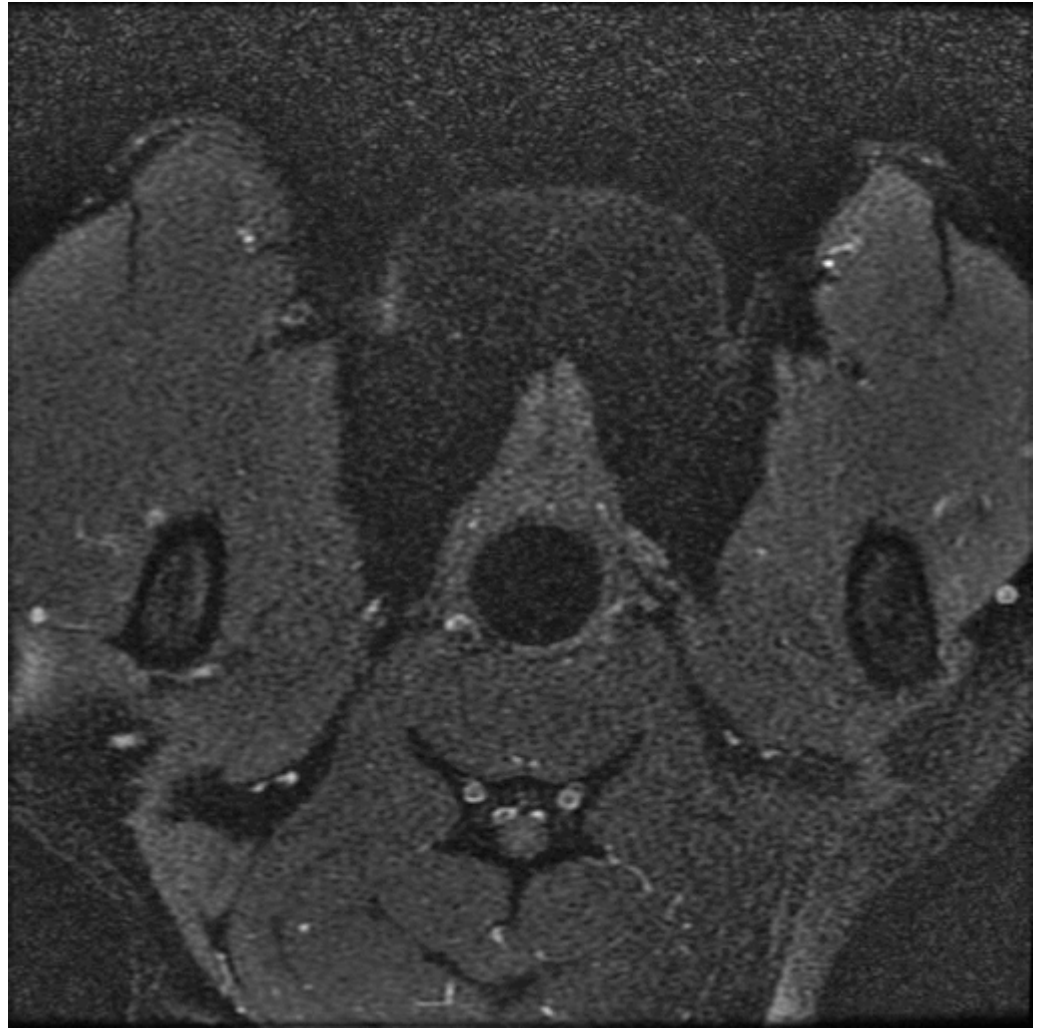
Brachial Plexus: Root

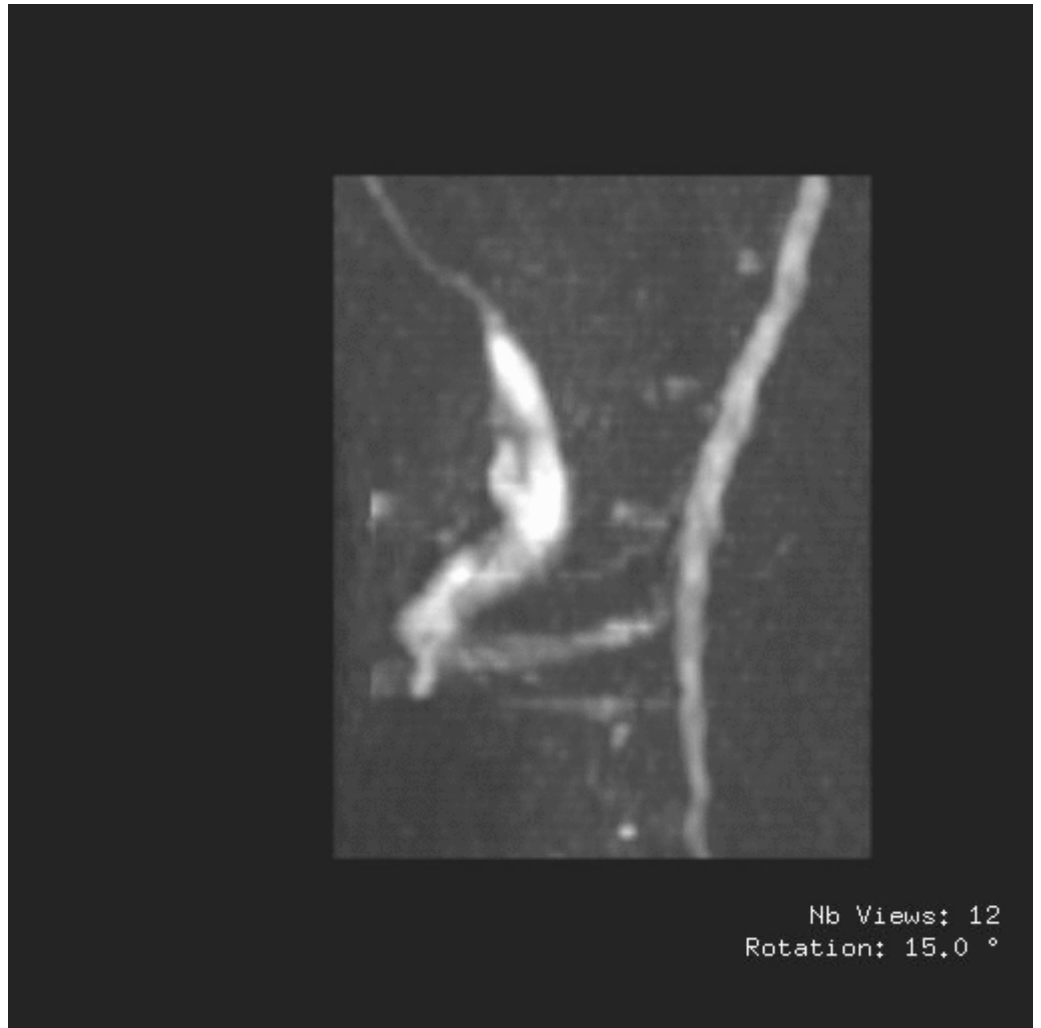
Brachial Plexus: Thickened Nerve

Brachial Plexus: Peripheral









From:
<https://wiki.virtual-scan.com/> - Knowledge Portal

Permanent link:
https://wiki.virtual-scan.com/doku.php?id=plexus_pathology&rev=1781153812

Last update: **2026/06/11 04:56**

