

Veterinary Shoulder MRI Guide (v1)

By: Scott Johnson MS RT (R)(MR)

Positioning

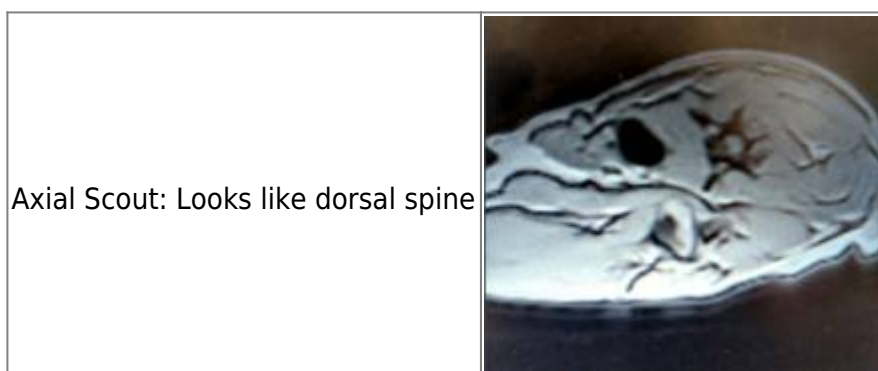
- Spine Coil
- Side of interest down
- Wedge under sternum
- Pull side up forelimb caudally
- Pull side down forelimb cranially until humerus is roughly perpendicular to sternum
- The idea is to get the forelimb in a relatively neutral position
 - **PALPATE SHOULDER JOINT**
 - **NOTE WHICH COILS THE JOINT IS OVER**
- 34 or 345 etc etc

First steps before scanning

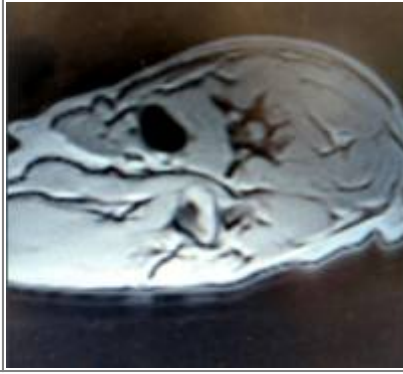1. Register patient
2. Adjust patient position to be either Left or Right decubitus, depending on side of interest
3. Open first scout image
4. Change spine coil selection to match the coils you noted inside the room
5. APPLY ALL
6. When in doubt, choose more coils

Second scout

1. Open scout
2. Maximize image
3. Click on 'report cursor'
4. Scroll through your images to find the shoulder joint on a transverse or a dorsal
5. Place cursor within the shoulder joint
6. Record the coordinates
 - Something like L30 P10 S20 etc
 - Will be different every patient
7. Input these coordinates with letters into the corresponding start/end points
8. Save, prep, scan



Dorsal Scout: Looks like axial spine



From:

<https://wiki.virtual-scan.com/> - **Veterinary MRI Wiki**

Permanent link:

https://wiki.virtual-scan.com/doku.php?id=shoulder_mri_guide&rev=1737066323

Last update: **2025/01/16 22:25**

